

# Subcutaneous calcinosis in a patient with anti-MDA5 positive dermatomyositis

Ruihong Hou<sup>1,2</sup>, Wei Du<sup>1,2</sup>, Liyun Zhang<sup>1,2</sup>, Ke Xu<sup>1,2,\*</sup>

<sup>1</sup>Shanxi Bethune Hospital, Shanxi Academy of Medical Sciences, Tongji Shanxi Hospital, Third Hospital of Shanxi Medical University, Taiyuan, China

<sup>2</sup>Tongji Hospital, Tongji Medical College, Huazhong University of Science and Technology, Wuhan, China

Received August 26, 2021 accepted September 08, 2021

A 21-year-old male was admitted because of heliotrope rash and proximal muscle weakness for 1 year and progressive shortness of breath for the preceding 2 months. His serum anti-melanoma differentiation-associated gene 5 (MDA5) antibody was positive and was diagnosed as dermatomyositis 1 year ago at the local hospital. He was treated with oral prednisone and intravenous cyclophosphamide 400 mg every 3 weeks for 10 months. His overall condition was stable until 2 months before admission.

Two months before admission, he developed fever and shortness of breath, which was getting worse gradually. Chest

Computed Tomography (CT) revealed interstitial lung disease. Therefore, he was treated with an increased dosage of glucocorticoid and intravenous immunoglobulin infusion combined with cyclophosphamide. However, his dyspnea had been getting worse and the subcutaneous tissue in both hips gradually hardened during hospitalization. On physical examination at admission, heliotrope rash was discovered on his bilateral eyelids. His right hip was hard to palpation. His arterial blood partial pressure of oxygen (PO<sub>2</sub>) was only 48.6 mmHg. Chest CT scan discovered pneumomediastinum. Meanwhile, a pelvic CT scan showed extensive subcutaneous calcinosis in both hips (Figure 1).<sup>[1, 2]</sup> His shortness

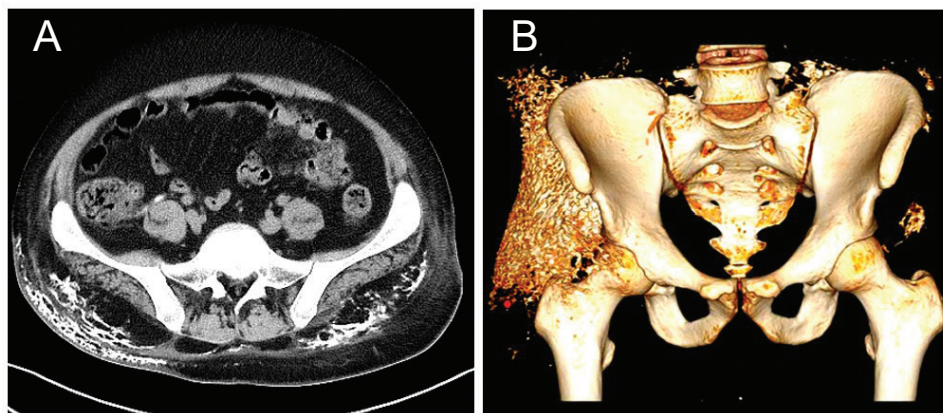


Figure 1: (A) CT cross-section reveals subcutaneous calcinosis of the pelvic wall (arrowheads); (B) CT stereo imaging of subcutaneous calcinosis (arrowheads).

#### Address for correspondence:

\*KeXu, Department of Rheumatology, Shanxi Bethune Hospital, Shanxi Academy of Medical Sciences, 99 Longcheng Street, Taiyuan 030032, Shanxi Province, China. E-mail: zhaoxuke@hotmail.com

of breath gradually improved after being treated with tofacitinib 5 mg twice a day<sup>[3]</sup> and intravenous cyclophosphamide 400 mg every 2 weeks, and his prednisone was tapered.

Three months later, chest CT showed interstitial lung disease but pneumomediastinum had disappeared.

#### Informed consent

---

*Informed consents have been obtained. The patient has given her consent for her images and other clinical information to be reported in the journal.*

#### Conflict of Interest

---

*None declared.*

#### References

---

[1] Saterenzoller E, Rizzo M, Harris A. Understanding Calcinosis Cutis. JAAPA. 2020;33(11):25–28.  
[2] Chung MP, Richardson C, Kirakossian D, *et al.* Calcinosis Biomarkers in Adult and Juvenile Dermatomyositis. Autoimmun Rev.

2020;19(6):102533.

[3] Kurtzman DJ, Wright NA, Lin J, *et al.* Tofacitinib Citrate for Refractory Cutaneous Dermatomyositis: An Alternative Treatment. JAMA Dermatol. 2016;152:944–945.