

## Ultrasonography in Preclinical Education: A Pilot Study

Virginia A. Syperda, DO, EdD, MBA; Puja N. Trivedi, OMS IV; Lauren C. Melo, OMS IV; Morganna L. Freeman, OMS IV; Eric J. Ledermann, OMS IV, MBA; Travis M. Smith, OMS IV; and James O. Alben, PhD

**Context:** Ultrasonography is a valuable diagnostic tool in the clinical setting. Yet, medical students often have minimal familiarity with this technology.

**Objective:** To evaluate the ability of second-year medical students to use ultrasonography for identification of anatomic structures and pathologic conditions.

**Design:** A self-directed approach that reduced facilitator involvement, encouraging learning that mimicked the medical school's problem-based learning pathway program.

**Methods:** Five students were each given 10 hours of instruction in ultrasonographic techniques by three certified ultrasonographers in outpatient and hospital settings. Each student performed 40 hours of organ-specific ultrasonographic scans on another student in 2-hour sessions during 20 weeks. Images were archived for future evaluation and quality rating. Students took a 35-question posttraining examination with 10 contrived case scenarios. Questions were designed to test student knowledge in three categories: anatomic structure, technical skill, and clinical diagnosis.

**Results:** Posttraining examination results, expressed as the percent of correct answers for all five participants by category, were as follows: anatomic structure, 70%; technical skill, 70%; clinical diagnosis, 68%. Evaluations of the archived images, which were graded for proper anatomic identification and image clarity, yielded the following scores indicating "good" or "fair" quality for each anatomic region: abdominal, 80%; pelvic, 63%; cardiac, 73%.

**Conclusion:** Second-year osteopathic medical students can attain a sufficient degree of proficiency in limited ultrasonographic technique.

*J Am Osteopath Assoc.* 2008;108:601-605

Ultrasonography is a noninvasive, accurate, and expeditious diagnostic tool that is underemphasized during undergraduate medical education. Although it is commonly used across a broad spectrum of medical subspecialties and has demonstrated life-saving diagnostic capabilities, most medical schools in the United States rely solely on clerkship and residency experiences to equip medical students with ultrasonography skills.<sup>1-3</sup>

Clerkships and residencies typically provide minimal training in ultrasonographic techniques. Even at the postgraduate level of medical education, diagnostic use of ultrasonography is limited, with a lack of standardization among training programs.<sup>1,4</sup> Therefore, it seems prudent and sensible to introduce sonographic techniques at the undergraduate level. Such introductions would increase physician expertise with diagnostic imaging technology and improve the quality of patient care.<sup>4</sup>

At Lake Erie College of Osteopathic Medicine-Bradenton (LECOM-Bradenton) in Fla, we conducted a pilot study to assess the ability of second-year medical students to learn ultrasonographic scanning techniques. Students were required to obtain images of satisfactory quality for diagnosis and to apply their knowledge of normal anatomic structure to the identification of basic pathologic conditions using ultrasonographic imaging tools.

A self-directed learning approach was selected for the present study because it duplicates the problem-solving skills required of practicing physicians—and it is the teaching format used for preclinical education in the problem-based learning pathway program at LECOM-Bradenton.<sup>5</sup>

Before consulting a radiologist or ultrasonographic technologist, students were encouraged to use the Internet, published literature, and radiology textbooks<sup>6,7</sup> in addition to working collaboratively to answer theoretical and practical questions. This type of early hands-on experience with ultrasonography is thought to foster active learning within the sciences and clinical practice, to increase student interest in medical imaging and radiology, and to help them become more knowledgeable consumers of radiologic services in the future.<sup>8</sup>

### Methods

The institutional review board at LECOM in Erie, Pa, approved all procedures used in the present study. Participating stu-

From Lake Erie College of Osteopathic Medicine-Bradenton in Fla.  
Address correspondence to Virginia A. Syperda, DO, Clinical Professor of Radiology, Lake Erie College of Osteopathic Medicine-Bradenton, 233 Rue des Lacs, Tarpon Springs, FL 34688-8608.  
E-mail: vsyperda@mindspring.com

Submitted May 21, 2007; accepted July 12, 2007.

## MEDICAL EDUCATION

dents signed permission forms that described the research intent of the project and the requirement that subjects have no known physical conditions (eg, prolapsed heart valve, gallstones) that would disqualify them from participation as “anatomically normal” subjects.

Five second-year osteopathic medical students, three women (P.N.T., L.C.M., M.L.F.) and two men (E.J.L., T.M.S.), participated in this 20-week pilot study. None of the students had prior experience using ultrasonographic techniques.

Two radiologists (including V.A.S.) certified by the American Osteopathic Board of Radiology (AOBR) served as evaluators of students’ ultrasonographic images. Each radiologist had extensive ultrasonography experience in the hospital setting. Three registered and certified ultrasonographic technologists instructed students in ultrasound technique, with two of these individuals also helping to evaluate students’ ultrasonographic images. Like the radiologists, all three technologists had extensive experience using ultrasonography in the clinical setting.

On study enrollment, students received an orientation to two portable ultrasonographic imaging devices provided by the manufacturer (SonoSite 180 TITAN; SonoSite Inc, Bothell, Wash). An experienced and certified ultrasonographer from SonoSite Inc provided students with a demonstration of the capabilities of the ultrasonographic instrument and a technical manual that described its basic functions.

Each student participating in the present study received approximately 10 hours of technical instruction and orientation from ultrasonographers. Instruction included techniques for adjusting image depth, using the enlargement function, freezing and labeling images, and measuring anatomic structures. The importance of using probes of various frequencies was covered. Also discussed and demonstrated were normal ultrasonographic findings of differing echogenicities, shadowing artifacts, and the use of the Doppler function to tracking blood flow.

Under the supervision of a radiologist from the LECOM-Bradenton faculty (V.A.S.), participating students performed ultrasonographic scans on each other in a series of imaging sessions. Each student participated in scanning sessions for an average of 2 hours per week for 20 weeks. This training schedule resulted in a total scanning time of about 40 hours per student. In these sessions, each student was required to perform scans of the abdominal region, pelvic region (via the transabdominal route), and cardiac region of another student enrolled in the study.

To maintain consistent anatomic structures in the images, pelvic scans were performed on women only. A woman who was also an osteopathic medical student but not otherwise participating in the present study served as a standardized patient for the pelvic scans during orientation and on request during scanning sessions.

Each student compiled a portfolio of 15 ultrasonographic images (Figure 1).<sup>10</sup> Each portfolio included 10 images from the

### Checklist

#### ■ Abdominal Region

- Hepatic confluence
- Right portal vein
- Left portal vein
- Diaphragm interface
- Sagittal gall bladder
- Transverse gall bladder
- Gall bladder wall thickness
- Sagittal right kidney
- Transverse right kidney
- Aorta with left lower lobe

#### ■ Pelvic Region (Woman)

- Sagittal uterus
- Right ovary
- Left ovary

#### ■ Cardiac Region

- Apical four-chamber
- Parasternal two-chamber

**Figure 1.** The 15 anatomic structures in three anatomic regions examined with ultrasonography by second-year medical students at Lake Erie College of Osteopathic Medicine-Bradenton in Fla.<sup>10</sup> Each student compiled a portfolio of ultrasonographic images for evaluation by radiologists and ultrasonographic technologists.

abdominal region, three from the pelvic region, and two from the cardiac region. Scans were archived for future evaluation as each anatomic region was examined.

### Student Evaluations

At the end of the 20 weeks of scanning sessions, students were presented with an electronic 35-question posttraining examination created in Microsoft Office PowerPoint (Microsoft Office 2003; Microsoft Corp, Redmond, Wash). The examination, which was devised by an AOBR-certified radiologist, consisted of 10 contrived case scenarios (Figure 2), each of which described a patient’s presenting symptoms or pertinent findings with corresponding ultrasonographic images and questions in multiple-choice or short-essay format. The

## Checklist

- Case 1: Benign Liver Mass
- Case 2: Normal Uterus
- Case 3: Appendicitis
- Case 4: Cholelithiasis
- Case 5: Epididymitis
- Case 6: Renal Cyst
- Case 7: Ruptured Spleen
- Case 8: Ruptured Spleen With Contrast
- Case 9: Bladder Mass
- Case 10: Ventricular Septal Defect

**Figure 2.** *The pathologic and normal conditions featured in 10 contrived case scenarios that were presented in an electronic 35-question posttraining examination created in Microsoft Office PowerPoint (Microsoft Office 2003; Microsoft Corp, Redmond, Wash). Second-year osteopathic medical students at Lake Erie College of Osteopathic Medicine-Bradenton in Fla, were trained in the use of ultrasonography by two board-certified radiologists. On this examination, case scenarios provided presenting symptoms or pertinent findings with corresponding ultrasonographic images and questions.*

questions were divided into three categories: anatomic structure (10 questions), technical skill (12 questions), and clinical diagnosis (13 questions). Student scores for this examination were collectively reported as the percent of correct answers in each of the three categories.

The quality of the archived ultrasonographic images of the abdominal, pelvic, and cardiac regions were evaluated by the two radiologists and two ultrasonographic technologists based on a 3-point rating system. If the image was judged to be of superior quality in clarity so that it would definitely provide sufficient information for an accurate diagnosis, it was given a rating of 2 points (a “good” rating). If the image was judged to have enough clarity that it might provide sufficient information for an accurate diagnosis, it was given a rating of 1 point (a “fair” rating). If the image did not include the anatomic structure of interest, if it was mislabeled, or if it was judged to be of insufficient quality for diagnostic purposes, it was given a rating of 0 (a “poor” rating).

### Results

On the 35-question posttraining examination, students scored an overall average of 69%. This score was the average of the percent of questions answered correctly in each of the three

question categories. Students achieved a score of 70% for the 10 questions on anatomic structure (ie, 35 correct answers out of 50 total answers); 70% for the 12 questions on technical skill (including especially high scores for questions about terminology, machine settings, and transducer frequencies); and 68% for the 13 questions on clinical diagnosis.

One of the technologists disqualified herself from evaluating student-submitted cardiac images because of certification issues.

Students archived a total of 75 ultrasonographic images (15 each) of the abdominal, pelvic, and cardiac regions. The overall image quality average was calculated by dividing the total number of points earned by the maximum number of possible points. Because each image could receive a maximum of 2 points by each of the four evaluators, the maximum total points would have been 600 (150 × 4) for 300 image evaluations. However, one of the evaluators graded only 13 of 15 images for each student, so the maximum possible points from all the evaluators was actually 580 for 290 image evaluations.

Good and fair images comprised 57% (166 images) and 37% (107 images), respectively, of the 290 image evaluations, with poor images making up the remaining 6% (17 images). The good and fair images represented a total of 439 points out of the possible 580 points, for a combined average of 76%.

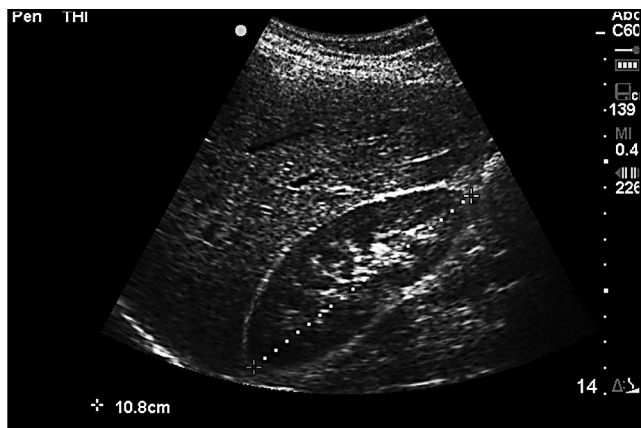Of the three anatomic regions examined with ultrasonography, the highest quality images were of the abdominal region (Figure 3); lowest quality images, pelvic region (Figure 4). The image quality score for each anatomic region was tabulated by adding the “good” and “fair” points earned by all five students from all four evaluators and dividing that number by the total number of possible points for that anatomic region. Resulting ratings were as follows: abdominal region, 80% (320 of 400 possible points); pelvic region, 63% (75 of 120 possible points); cardiac region, 73% (44 of 60 possible points). The primary criteria for image rejection and classification of images as poor in quality included incorrect gain level and mislabeling.

### Comment

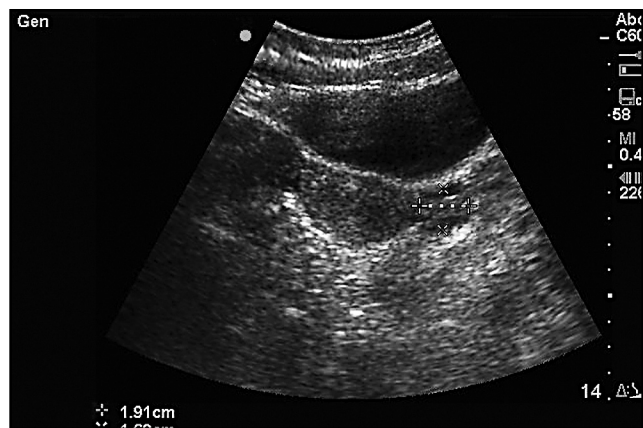
The present pilot study used a self-directed learning approach to assess the ability of medical students to work together with minimal guidance to improve their understanding and use of ultrasonography, including high-quality image acquisition. This approach was chosen because it reflects the manner in which physicians learn and use ultrasonography during and after residency training.<sup>5</sup>

In addition, this approach reduces instructor involvement and time commitment, and student-directed training can be performed at students’ convenience.

Self-directed learning fosters an educational environment in which students actively solve problems, identify gaps in their knowledge and conceptual understanding, and take responsibility for their own learning.<sup>5,9</sup>



**Figure 3.** A sample ultrasonographic image of the sagittal right kidney made by a second-year osteopathic medical student at Lake Erie College of Osteopathic Medicine-Bradenton in Fla. An image of this anatomic structure was among 10 ultrasonographic images each student was required to make of the abdominal region.



**Figure 4.** A sample ultrasonographic image of the transverse uterus with left ovary made by a second-year osteopathic medical student at Lake Erie College of Osteopathic Medicine-Bradenton in Fla. An image of this anatomic structure was among three ultrasonographic images each student was required to make of a woman's pelvic region.

By allowing students to make ultrasonographic scans of each other, we hoped that they would gain a more thorough knowledge of clinical applications, as well as learn to better appreciate normal variants and to make connections between basic medical sciences and clinical practice.

Ultrasonography is a relatively inexpensive and noninvasive diagnostic tool that instantly provides detailed, specific answers to medical questions.<sup>3</sup> The clinical usefulness and life-saving potential of ultrasonography are well known. Ultrasonography is now a central component of patient treatment and disease management across a broad spectrum of medical subspecialties.<sup>1-3</sup> Regardless of specialty choice, medical students are likely to encounter ultrasonography in medical practice. Therefore, they need to acquire a solid understanding of this technology and its clinical applications to maximize health benefits for their patients.<sup>10</sup>

Participating students demonstrated proficiency in the understanding of anatomic structures shown in ultrasonographic images and in the technical aspects of obtaining ultrasonographic images, including terminology, machine settings, and transducer frequencies. Students demonstrated slightly poorer performance on clinical application of this knowledge. Still, their level of clinical proficiency was more than adequate considering they had no prior training in the use of this technology for detecting the pathologic conditions depicted in the case scenarios.

Based on the radiologists' and technologists' analyses of student-submitted ultrasonographic images, students demonstrated proficiency in the imaging of intended organ systems, but they showed deficiencies in effective use of such technical modalities as gain and depth adjustment. The main reasons for image rejection included poor gain adjustment and failure to

capture the entire anatomic target in a single image. These deficiencies represent areas in which increased emphasis should be focused in future instruction. The degree of difficulty for displaying uterine and ovarian detail was increased by the ethical requirements applied to the present study's methodology. To preserve the modesty and personal privacy of the student volunteer who served as a standardized patient for pelvic sonography, the transabdominal route was used.

The present study suggests that approximately 10 hours of instruction and 40 hours of postinstruction scanning sessions are sufficient to provide second-year medical students with a clinically useful understanding of the basic principles and techniques of ultrasonography. Based on their posttraining examination results, students obtained satisfactory levels of ultrasonographic image interpretation and clinical application of this knowledge.

### **Current Deficiencies in Ultrasonography Education**

Traditionally, medical students are introduced to ultrasonography during their clerkship and residency training years. However, previous studies have suggested that exposure to this technology during medical training is highly variable.<sup>1-4</sup> According to a survey of 365 final-year medical students by Remmen et al,<sup>2</sup> medical schools cannot depend on clerkship experiences alone to provide their students with adequate training in basic clinical skills, including ultrasonography.

There is a lack of consensus regarding what constitutes adequate training in ultrasonography, and means of standardizing minimal levels of knowledge about this technology are currently unavailable.<sup>4</sup> Therefore, it would be of notable benefit for medical schools to incorporate a hands-on introduction to diagnostic sonography at the undergraduate level



of medical education. Early introduction to this technology would ensure that all new physicians have a basic foundation in practical ultrasonographic techniques—a foundation on which they could build in the future.<sup>4</sup>

Currently, medical school education in radiology is often limited to passive experiences for students—observation of radiologists and residents at work, with little or no student participation in image collection or evaluation.<sup>9</sup> Challenges in improving radiology education include the large amount of technical training that is required before medical students can begin to benefit from the use of this technology, as well as the difficulties students may have in comprehending clinically important material when they have little or no prior training in radiology.<sup>3,9</sup> Nevertheless, previous studies<sup>5,11</sup> have suggested that undergraduate medical students can obtain a resident-level understanding of ultrasonography provided that they are given proper means and methods of training. Considering its cost-effective nature, portability, and wide clinical application, ultrasonography provides an ideal teaching tool for undergraduate medical students.

### Study Limitations

There are several limitations to the present study. As a pilot project, it was a short-term study conducted with a small number of student participants. Another potential limitation to the present study is that its design lacked a pretraining examination of student knowledge for baseline comparisons. It was assumed that, because all student participants had minimal previous training in ultrasonography, administration of such an examination would not reveal noteworthy information.

Yet another potential limitation to the study is that students were not tested on their ultrasonographic scanning techniques by direct observation. Instead, it was assumed that the high quality of students' ultrasonographic images would be a reflection of proper technique.

### Conclusion

It was our goal to investigate a novel approach to ultrasonography education that reduced facilitator involvement and fostered an active learning environment for medical students. Based on the results of our pilot study, it can be concluded that second-year osteopathic medical students can satisfactorily comprehend and apply ultrasonographic principles in hypothetical models of clinical settings. This result strongly supports the integration of ultrasonographic imaging technology into the undergraduate medical school curriculum.

Future areas of research could focus on the application of ultrasonography as part of the anatomy laboratory experience, using real-time ultrasonographic imaging to give medical students a view of "living anatomy."

### Acknowledgments

We thank April Roy, RDMS, and SonoSite Inc of Bothell, Wash, for their generous provision of SonoSite TITANT<sup>TM</sup> portable ultrasonography units for use during the duration of the present study. We also thank Frank Matheu, DO; Linda Todoric, RDMS; and Linda Woodbury, RDCS, for their feedback; and Elizabeth Sanchez, BS, for her assistance in editing this article in manuscript form.

### References

- Heller MB, Mandavia D, Tayal VS, Cardenas EE, Lambert MJ, Mateer J, et al. Residency training in emergency ultrasound: fulfilling the mandate. *Acad Emerg Med*. 2002;9:835-839.
- Remmen R, Derese A, Scherpbier A, Denekens J, Hermann I, van der Vleuten C, et al. Can medical schools rely on clerkships to train students in basic clinical skills? *Med Educ*. 1999;33:600-605.
- Shapiro RS, Ko PK, Jacobson S. A pilot project to study the use of ultrasonography for teaching physical examination to medical students. *Comput Biol Med*. 2002;32:403-409.
- Arger PH, Schultz SM, Sehgal CM, Cary TW, Aronchick J. Teaching medical students diagnostic sonography. *J Ultrasound Med*. 2005;24:1365-1369.
- Collins J, Riebe JD, Albanese MA, Dobos N, Heiserman K, Primack SL, et al. Medical students and radiology residents: can they learn as effectively with the same educational materials? *Acad Radiol*. 1999;6:691-695.
- Curry RA, Tempkin BB. *Sonography: Introduction to Normal Structure and Function*. 2nd ed. St Louis, Mo: Saunders; 2004.
- Sanders RC. *Clinical Sonography: A Practical Guide*. 3rd ed. Philadelphia, Pa: Lippincott Williams & Wilkins; 1998.
- Ganske I, Su T, Loukas M, Shaffer K. Teaching methods in anatomy courses in North American medical schools: the role of radiology. *Acad Radiol*. 2006;13:1038-1046.
- Erinjeri JP, Bhalla S. Redefining radiology education for first-year medical students: shifting from a passive to an active case-based approach. *Acad Radiol*. 2006;13:789-796.
- Subramaniam RM, Beckley V, Chan M, Chou T, Scally P. Radiology curriculum topics for medical students: students' perspectives. *Acad Radiol*. 2006;13:880-884.
- Yoo MC, Villegas L, Jones DB. Basic ultrasound curriculum for medical students: validation of content and phantom. *J Laparoendosc Adv Surg Tech A*. 2004;14:374-379. Available at: <http://www.liebertonline.com/doi/abs/10.1089%2FFlap.2004.14.374>. Accessed September 11, 2008.