

# Anti-granulocyte scintigraphy in early rheumatoid arthritis – does it work?

## Research Article

Edit Horkay<sup>1</sup>, Gyöngyvér Kincse<sup>2</sup>, József Varga<sup>3</sup>, Lajos Szabados<sup>4</sup>, Ildikó Garai<sup>4</sup>,  
János Gaál<sup>2\*</sup>

*1 University of Debrecen, Medical & Health Sciences Centre, Department of Radiology  
H-4032 Debrecen, Nagyerdei krt. 98., Hungary*

*2 'Kenézy Gyula' Hospital, Department of Rheumatology,  
H-4043 Debrecen, Bartók Béla u. 2-26., Hungary*

*3 University of Debrecen, Medical & Health Sciences Centre, Department of Nuclear Medicine  
H-4032 Debrecen, Nagyerdei krt. 98, Hungary*

*4 University of Debrecen, Medical & Health Sciences Centre, PET-CT Medical Diagnostics Ltd.  
H-4032 Debrecen, Nagyerdei krt. 98, Hungary*

Received 30 October 2012; Accepted 29 January 2013

**Abstract:** Objective. To compare the performance of anti-granulocyte scintigraphy with those of widely used prognostic indices (such as DAS28, anti-CCP, early MRI imaging). Methods. Twenty-five patients with early arthritis were enrolled into the study. Following the review of clinical data and the evaluation of disease activity, we performed MRI imaging of the hands, anti-granulocyte scintigraphy, and determined anti-CCP positivity. The relationship between the changes of MRI scores and the above prognostic factors were analyzed statistically. Results. At baseline, values were as follows: DAS28  $3.86 \pm 1.19$ , CRI  $0.15 \pm 0.12$ , MRI erosions and synovitis scores  $25.11 \pm 12.82$  and  $4.32 \pm 4.02$  (respectively), the ratio of anti-CCP positivity was 7/12 (58%). After the follow-up period of  $13.6 \pm 2.52$  months, erosion and synovitis scores were  $43.11 \pm 22.23$ , and  $5.32 \pm 6.16$ , respectively ( $p=0.001$  and  $p=0.015$ ). The occurrence of new erosions was correlated with baseline erosion score ( $k=0.523$ ,  $p=0.022$ ) and anti-CCP positivity ( $p=0.021$ ). The relationship between CRI and baseline synovitis score was strong ( $=0.518$ ,  $p=0.023$ ), whereas it was weak only between the former and baseline erosion score ( $=0.402$ ,  $p=0.08$ ). Conclusion. As shown by this study, potential markers for predicting subsequent destructiveness in early RA include MRI and anti-CCP testing, primarily. <sup>99m</sup>Tc labeled anti-granulocyte joint scintigraphy is appropriate for the objective and quantitative appraisal of disease activity.

**Keywords:** Prediction of erosiveness • Leukocyte accumulation • MRI • Anti-granulocyte scintigraphy • Anti-CCP positivity

© Versita Sp. z o.o

## 1. Introduction

Rheumatoid arthritis (RA) is a chronic, immune-mediated, polyarticular inflammatory disorder, which afflicts approximately 1 percent of the adult population and leads to the gradual destruction of involved joints. RA is associated with a substantial deterioration in quality of life; moreover, it also reduces life expectancy. Therefore, early recognition and the prediction of subsequent

prognosis and therapeutic efficacy are issues of utmost importance. In early RA (diagnosed 2 years previously, at the earliest), several prognostic factors potentially useful for predicting the expected outcome of the disease are noted in the literature. Predictors implicated with a higher probability of a poorer prognosis and evolution of destructive lesions include rheumatoid-factor positivity [1], the presence of IgA-type rheumatoid factors [2], and rheumatic nodules, female gender [3], and

\* E-mail: gaalja@freemail.hu

the abnormalities of the synovial fluid (leukocytosis, acidosis) [4]. New biological markers providing information on the destruction and renewal of articular cartilage have been identified. Cartilage oligomeric matrix protein (COMP), for example, has been suggested by Tseng *et al* as a potential diagnostic and prognostic marker, also suitable for monitoring therapeutic efficacy [5]. Fujikawa *et al* [6] reported similar findings. Syversen *et al* presumed a weak correlation between joint destruction and the elevated serum level of collagen cross-linked C-telopeptide (CTX-1), an established marker of bone resorption [7]. The serum levels of a variety of aggrecan molecules and their fragments have also been suggested as prognostic markers. Rousseau *et al* detected a significant reduction of total aggrecan level, along with the presence of at least one specific subpopulation of aggrecan fragments [8]. Remarkable laboratory indexes of prognostic value include anti-citrullinated protein/peptide antibodies (ACPA) and anti-mutant-citrullinated vimentin antibodies (anti-MCV). According to Syversen *et al*, the presence of the latter is as reliable a predictor of subsequent articular destruction as anti-CCP positivity [9]. Imaging studies are additional, important supplements to laboratory testing.

According to clinical observations, neutrophil leukocytes predominate in the cell population in joints afflicted by active RA. Therefore, the accumulation of leukocytes may be regarded as an essential event in rheumatoid synovitis [10]. Although leukocyte infiltration can be detected by scintigraphy, the value of this finding regarding the subsequent evolution of erosion is unknown [11].

Our study, conducted on patients with early rheumatoid arthritis (characterized by a disease duration shorter than a year), was intended to ascertain the prognostic value of <sup>99m</sup>Tc-labeled leukocyte scintigraphy in predicting the eventual outcome of the disease process, especially the occurrence of erosions.

## 2. Materials and methods

### 2.1. Patients

Twenty-five patients who had been followed at the Early Arthritis Center of 'Kenézy Gyula' Hospital were enrolled. The patient-collection period started in December, 2008 and ended in December, 2009. All patients fulfilled the American College of Rheumatology (ACR) 1987 criteria of RA [12]. By the end of the follow-up period of 1 year, on average, clinical and laboratory data were available for 19 out of the 25 patients. Six patients were lost to follow up, 2 withdrew the informed consent, 3 refused the regular controls during the study because of traffic

difficulties, and 1 patient moved from the city and became unreachable.

### 2.2. Methods

Upon inclusion of the patients, we reviewed clinical and laboratory data. Magnetic resonance imaging (MRI) of the hands was obtained to diagnose and quantify the synovitis, and then planar joint scintigraphy was performed using Fab' fragments of monoclonal, <sup>99m</sup>Tc-labeled anti-granulocyte antibodies (anti-NCA-90, sulesomab, LeukoScan®). MRI and scintigraphy were performed at intervals of 2 weeks, at the most. The clinical and laboratory parameters of the patients were followed for a year, on average. RA was managed with pharmacotherapy chosen by the rheumatologist responsible for the patient's medical care, in view of clinical disease activity. MRI was repeated after a year, on average. We correlated the severity of new erosions and synovitis with baseline findings of MRI and scintigraphy.

The statistical methods were the Kolmogorov–Smirnov test to investigate the normality of the data distribution, the Pearson's correlation test for seeking the correlation between the clinical and scintigraphic data, the independent samples t-test to seek the relationship between anti-CCP positivity and the development of new erosions and synovitis, and paired samples t-test for evaluation of the changes in MRI scores (erosion and synovitis).

The results were regarded to be significant if the p value was <0.05. The study protocol was approved by the Institutional Review Board of the University of Debrecen Medical and Health Sciences Center; and a written, informed consent was obtained from all.

MRI was performed with equipment specifically designed for imaging of the extremities (E-scan 0.2 T, Esaote Biomedica, Geneva, Italy) on recumbent patients. Native and gadolinium-enhanced (0.1 mmol/kg b. w. Gd-DTPA, Magnevist®, Schering, Berlin, Germany) coronal T1- and T2-weighted, short tau inversion recovery (STIR), as well as three-dimensional T1-weighted images were obtained, along with axial T1-weighted scans (Figure 2.). We evaluated the images according to the method described by Klarlund *et al* in 2005 [13]. We appraised the erosions individually in 14 localizations, all together (including the radial and ulnar epiphyses, all carpal bones, and the 2<sup>nd</sup> through 5<sup>th</sup> metacarpal heads) by absolute numbers and greatest diameters. Using the greatest diameters, we determined the mean surface area of erosions in the studied regions and then aggregated the scores.

The synovitis score was evaluated semi-quantitatively, according to a four-grade scale (0 = no synovial

thickening, 1 through 3 = mild/moderate/severe thickening) for each region, and then individual scores were aggregated. The extent of synovitis was determined in the distal radioulnar and intercarpal joints and in the second through fifth metacarpophalangeal joints (6 localizations, total) – thus, a maximal score of 18 could be achieved. This was increased further by the tenosynovitis score, which was “1” in the presence of detectable synovial inflammation and “0” in its absence.

During the scintigraphy,  $^{99m}\text{Tc}$  sulesomab (LeukoScan, Immunomedics GmbH, Germany), 800 MBq, was injected intravenously. The injected radioactivity was measured with a dose calibrator and converted to counts per second with use of the calibration factor measured for the camera-collimator system previously. Static images of the wrists and hands were obtained 4 hours after the administration of the radiopharmaceutical. The images were obtained as 128 x 128 matrices over 5 minutes, using an MB-9200 gamma camera (Gamma Move, Hungary) equipped with a LEGP (low energy general purpose) collimator. The images were evaluated visually in a qualitative manner (for increased radiopharmaceutical uptake), and the regional uptake of the radiopharmaceutical was calculated for the hands. Regions of interest (ROIs) were drawn around the wrists and the hands (Figure 3), and their uptake was expressed as a percentage of the injected dose (corrected for Tc decay). We aggregated regional radiopharmaceutical uptake measured in the joints into a single uptake parameter (cumulative radiopharmaceutical uptake index [CRI]).

### 3. Results

The essential clinical parameters of the study population are shown in Figure 1. At baseline, the mean age of patients was  $53.5 \pm 11.9$  years, the female-to-male ratio was 15:4, and the mean disease duration was  $4.97 \pm 3.03$  months. The clinical activity of synovitis was in the moderate range, as shown by the three-item activity index evaluating 28 joints (DAS28) of  $3.83 \pm 1.19$ . Seven patients received methotrexate, one patient each was receiving hydroxychloroquine or sulfasalazine monotherapy; five underwent combination therapy with hydroxychloroquine and methotrexate. Additional combinations for one patient each comprised methotrexate with sulfasalazine, methotrexate with sulfasalazine and hydroxychloroquine, and methotrexate with hydroxychloroquine and leflunomide. Finally, two patients were treated with methotrexate, sulfasalazine, and leflunomide as first-line combination therapy. Fifteen patients required transient glucocorticoid therapy over a period

of  $4.28 \pm 1.46$  months, on average. Eleven of the nineteen patients (58%) were rheumatoid-factor-positive, whereas the proportion of patients who were anti-CCP (anti-cyclic citrullinated peptide)-positive was 37% (7/19 patients).

The baseline erosion score of the hands on MRI was  $25.11 \pm 12.82$ ; the initial synovitis score was  $4.32 \pm 4.02$ , and the cumulative radiopharmaceutical uptake index (CRI) was  $0.15 \pm 0.12$ . By the end of the follow-up period of  $13.26 \pm 2.52$  months, the erosion score on MRI and synovitis score changed to  $43.11 \pm 22.23$  and  $5.32 \pm 6.16$ , respectively ( $p=0.001$  and  $p=0.015$ ).

We did not find statistically significant relationships between patient age, gender, and disease duration or rheumatoid-factor positivity or the occurrence of erosions.

DAS28 and initial synovitis scores, by contrast, were closely related ( $k=0.622$ ,  $p=0.042$ ). The occurrence of new erosions was related both to the initial erosion score ( $k=0.523$ ,  $p=0.022$ ), and to anti-CCP positivity ( $p=0.021$ ).

As shown in Figure 4, the CRI measured by scintigraphy was correlated with anti-CCP positivity ( $p=0.048$ ), as well as with the baseline synovitis score ( $k=0.518$ ,  $p=0.023$ ), but not with the extent of erosions that had evolved during the 1-year follow-up period.

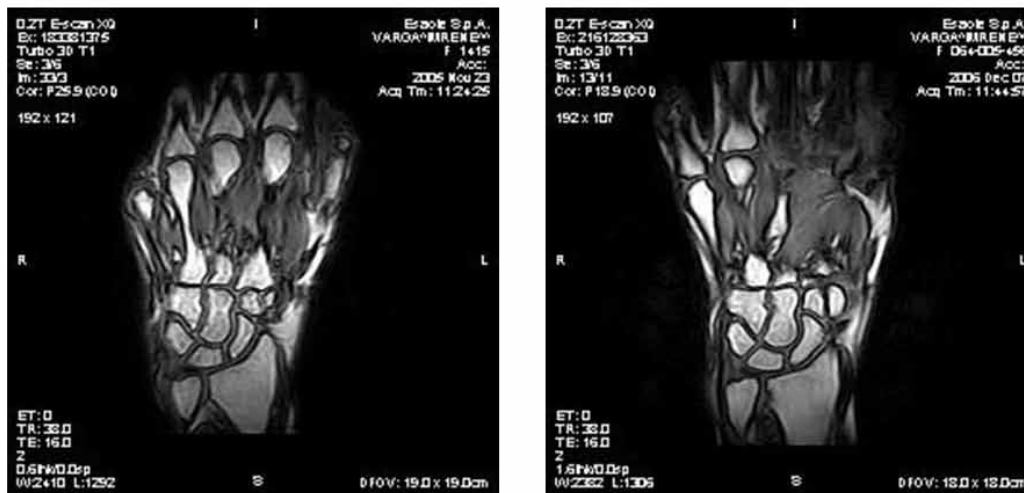
## 4. Discussion

The prevention of articular damage is the ultimate goal of the management of RA. The current therapeutic strategy is essentially determined by inflammatory activity, as this has been reasonably related to subsequent erosiveness. A variety of disease-activity indexes are used to characterize the intensity of arthritis. Disease Activity Score 28 (DAS28), which is the most widely used tool for this purpose [14], evaluates both objective components (number of swollen joints) and subjective elements (number of tender joints, subjective pain intensity assessed by the patient on a visual analogue scale), along with partially nonspecific variables (erythrocyte sedimentation rate [ESR] or C-reactive protein level). As a result, the reproducibility of articular indexes is at least questionable, considering the diverse pain perception thresholds of patients and the nonspecific character of ESR.

Many attempts have been made to quantify the activity of RA by diagnostic imaging modalities, including radionuclide studies, some of which may prove adequate for the purpose. Having evaluated the extent of bone-marrow edema with MRI of the hand, wrist, and feet in a 2-year study, Hetland *et al* considered this index

<b>Mean age (years)</b>	<b>53.5 ± 11.9</b>
<b>Female-to-male ratio</b>	<b>15/4</b>
<b>Mean disease duration (months)</b>	<b>4.97 ± 3.03</b>
<b>Baseline DAS28</b>	<b>3.86 ± 1.19</b>
<b>DMARD monotherapy (%)</b>	<b>9 (47%)</b>
<b>Combination therapy</b>	<b>10 (53%)</b>
<b>Steroid therapy</b>	<b>15 (79%)</b>
<b>RF positivity</b>	<b>11 (58%)</b>
<b>aCCP positivity</b>	<b>7 (37%)</b>

**Figure 1.** Essential clinical data of the study population



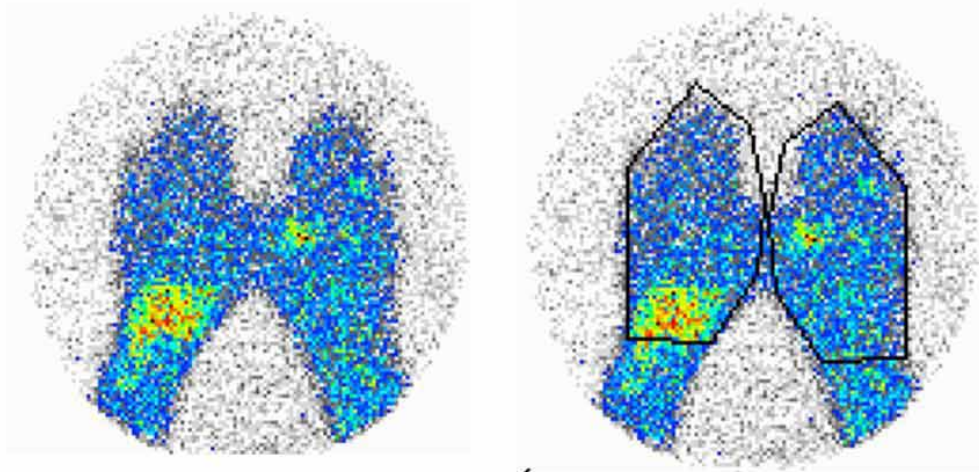
**Figure 2.** 3D T1-weighted MRI images of the region from the radiocarpal to the MCP joints of the same patient. Left: No erosions are visible on this baseline scan. Right: On this image obtained 13 months later, erosions are depicted on the lateral-radial surface of the distal radioulnar joint.

the strongest independent predictor of radiological progression [15]. Palosaari *et al* found a close relationship between bone-marrow edema and subsequent articular erosions in their 2-year study [16]. Ostgendorf *et al* studied the diagnostic efficacy of duplex ultrasound, positron emission tomography (PET), and mini-arthroscopy and found this combination useful for the early detection of pathomorphological abnormalities, as well as for the prediction of prognosis [17].

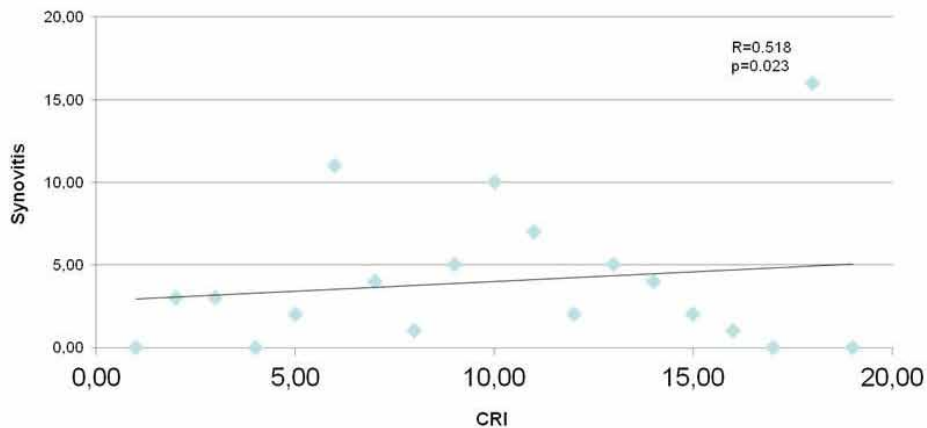
Van der Laken found that PET imaging of macrophages, undertaken after the [11C](R)-PK11195-labeling of their benzodiazepine receptors, offers a noninvasive means both for the detection of incipient synovitis and for the subsequent monitoring of its activity [18]. Studying 13 patients with RA with <sup>99m</sup>Tc-MDP joint scintigraphy,

Möttönen *et al* demonstrated a correlation between high scintigraphic activity and subsequent erosiveness. Their findings also suggested that erosions do not evolve in scintigraphically inactive joints [19].

De Bois *et al* performed <sup>99m</sup>Tc-IgG joint scintigraphy in 30 patients with early rheumatoid arthritis and found, after a 1-year follow-up period, that this form of radionuclide imaging might prove useful for the prediction of joint destruction [20]. Takalo *et al* reported similar results with <sup>99m</sup>Tc-nanokolloid joint scintigraphy [21]. Using <sup>99m</sup>Tc-HMPAO-leukocyte scintigraphy, our work group showed a relationship between the magnitude of articular leukocyte infiltration and the number of swollen joints [14].



**Figure 3.**  $^{99m}\text{Tc}$  anti-granulocyte scintiscan of the hands, with superimposed ROIs: the involvement of the left wrist and of the second MCP joint of the right hand are visible.



**Figure 4.** The relationship between the cumulative index of radioisotope uptake and baseline synovitis score.

No studies have been conducted to date to clarify the relationship between the extent of leukocyte infiltration and disease activity, or erosiveness. As suggested by the relationship between the CRI (cumulative) of the hands and anti-CCP positivity, as well as the MRI synovitis score,  $^{99m}\text{Tc}$ -labeled anti-granulocyte joint scintigraphy is appropriate primarily for the objective and quantitative appraisal of disease activity.

$^{99m}\text{Tc}$ -labeled anti-granulocyte scintigraphy should be performed when access to MRI is limited or nonexistent or the waiting list for MRI is long. Moreover, the cost of  $^{99m}\text{Tc}$ -labeled anti-granulocyte scintigraphy is

significantly lower than that of MRI, and being a commonly available (in any radioisotope diagnostic laboratory equipped with a gamma camera), rapid, and relatively straightforward test, it is a realistic alternative to MRI in cases where the objective appraisal of the activity of arthritis is important. High scintigraphic activity detected over the hands suggests a substantial leukocyte infiltration, which might require the early initiation of aggressive therapy.

Study limitations: the relatively low patient number, and the lack of a uniform treatment algorithm may be considered a potential flaw of this study.

## Declaration

The first two authors contributed equally to this work.

## References

- [1] Kellgren J.H., O'Brien W.M. On the natural history of rheumatoid arthritis in relation to the sheep cell agglutination test (SCAT), *Arthritis. Rheum.*, 1962, 5,115
- [2] Withrington R.H., Teitsson I., Valdimarsson H., Seifert M.H. Prospective study of early rheumatoid arthritis. II. Association of rheumatoid factor isotypes with fluctuations in disease activity, *Ann. Rheum. Dis.*, 1984, 43(5),679-685
- [3] Sharp J.T., Calkins E., Cohen A.S., Schubart A.F., Calabro J.J. Observations on the clinical, chemical, and serological manifestations of rheumatoid arthritis, based on the course of 154 cases, *Medicine (Baltimore)*, 1964, 43,41-58
- [4] Geborek P., Saxne T., Pettersson H., Wollheim F.A. Synovial fluid acidosis correlates with radiological joint destruction in rheumatoid arthritis knee joints, *J. Rheumatol.*, 1989, 16(4), 468-472
- [5] Tseng S., Reddi A.H., Di Cesare P.E. Cartilage Oligomeric Matrix Protein (COMP): A Biomarker of Arthritis, *Biomark. Insights*. 2009, 17(4),33-44
- [6] Fujikawa K., Kawakami A., Tamai M., Uetani M., Takao S., Arima K., et al., High serum cartilage oligomeric matrix protein determines the subset of patients with early-stage rheumatoid arthritis with high serum C-reactive protein, matrix metalloproteinase-3, and MRI-proven bone erosion, *J. Rheumatol.*, 2009, 36(6),1126-1129
- [7] Syversen S.W., Goll G.L., van der Heijde D., Landewé R., Gaarder P.I., Odegård S., et al., Cartilage and bone biomarkers in rheumatoid arthritis: prediction of 10-year radiographic progression, *J. Rheumatol.* 2009, 36(2), 266-272
- [8] Rousseau J.C., Sumer E.U., Hein G., Sondergaard B.C., Madsen S.H., Pedersen C., et al., Patients with rheumatoid arthritis have an altered circulatory aggrecan profile, *BMC Musculoskelet. Disord.*, 2008, 28, 9:74
- [9] Syversen S.W., Goll G.L., van der Heijde D., Landewé R., Lie B.A., Odegard, S., et al., Prediction of radiographic progression in rheumatoid arthritis and the role of antibodies against mutated citrullinated vimentin: results from a ten-year prospective study, *Ann. Rheum. Dis.*, 2010. 69(2), 345-351
- [10] Firestein G.S., Etiology and pathogenesis of rheumatoid arthritis, In: *Kelly's Textbook of Rheumatology* (Harris E.D.Jr, Budd R.C., Genovese M.C., Firestein G.S., Sargent J.S., Sledge B.C. eds) 7th ed. Oxford 2004, 996-1042
- [11] Gaál J., Mézes A., Síró B., Varga J., Galuska L., Jánoky G., et al., Tc99m HMPAO labeled leukocyte scintigraphy in patients with rheumatoid arthritis: a comparison with disease activity, *Nucl. Med. Commun.*, 2002, 23:39-46
- [12] Arnett F.C., Edworthy S.M., Bloch D.A., McShane D.J., Fries J.F., Cooper N.S., et al. The American Rheumatism Association 1987 revised criteria for the classification of rheumatoid arthritis, *Arthritis. Rheum.*, 1988, 31,;315-324
- [13] Klarlund M., Ostergaard M., Jensen K.E., Madsen J.L., Skjødt H., Lorenzen I., et al., Magnetic resonance imaging, radiography, and scintigraphy of the finger joints: one year follow up of patients with early arthritis. The TIRA Group, *Ann. Rheum. Dis.* 2000, 59(7),521-528
- [14] Fransen J., van Riel P.L., The Disease Activity Score and the EULAR response criteria, *Rheum. Dis. Clin. North. Am.*, 2009, 35(4),745-757
- [15] Hetland M.L., Ejbjerg B., Hørslev-Petersen K., Jacobsen S., Vestergaard A., Jurik A.G., et al. CIMESTRA study group., MRI bone oedema is the strongest predictor of subsequent radiographic progression in early rheumatoid arthritis. Results from a 2-year randomised controlled trial (CIMESTRA), *Ann. Rheum. Dis.*, 2009, 68(3), 384-390
- [16] Palosaari K., Vuotila J., Takalo R., Jartti A., Niemelä R.K., Karjalainen A., et al. Bone oedema predicts erosive progression on wrist MRI in early RA—a 2-yr observational MRI and NC scintigraphy study, *Rheumatology*, 2006, 45(12), 1542-1548
- [17] Ostendorf B., Schneider M., [Imaging beyond conventional radiography: mini arthroscopy, duplex ultrasonography and positron emission tomography] *Z. Rheumatol.*, 2003, 62(Suppl 2), II 37-40
- [18] van der Laken C.J., Elzinga E.H., Kropholler M.A., Molthoff C.F., van der Heijden J.W., Maruyama K., et al., Noninvasive imaging of macrophages in rheumatoid synovitis using 11C-(R)-PK11195 and

- positron emission tomography, *Arthritis. Rheum.*, 2008, 58(11), 3350-3355
- [19] Möttönen T.T., Hannonen P., Toivanan J., Rekonen A., Oka M. M., Value of joint scintigraphy in the prediction of erosiveness in early rheumatoid arthritis, *Ann. Rheum. Dis.*, 1988, 47, 183-189
- [20] de Bois M.H., Westedt M.L., Arndt J.W., Wiarda K.S., van der Velde E.A., Pauwels EK., et al., Value of <sup>99m</sup>Tc-IgG scintigraphy in the prediction of joint destruction in patients with rheumatoid arthritis of recent onset, *Rheumatol. Int.*, 1995, 15(4), 155-158
- [21] Takalo R., Niemelä R., Karjalainen A., Leisti E.L., Kautiainen H., Hakala M., (99m)Technetium nanocolloid scintigraphy in prognostication of early RA *Scand. J. Rheumatol.* 2011, 40(2), 152-153