

Case Report

Andrea Boni, Giovanni Cochetti, Angelo Sidoni, Guido Bellezza, Emanuele Lepri, Andrea De Giglio, Morena Turco*, Jacopo Adolfo Rossi De Vermandois, Michele Del Zingaro, Roberto Cirocchi, Ettore Mearini

Primary angiosarcoma of the kidney: case report and comprehensive literature review

<https://doi.org/10.1515/med-2019-0048>

received February 14, 2019; accepted April 24, 2019

Abstract: Purpose: Angiosarcoma (AS) is an aggressive malignant tumour of endothelial origin, most frequently compelling the skin. The kidney is a rare site of primary occurrence of AS with a quite challenging diagnosis and poor prognosis, mainly due to its raw metastasising power. We described our first case of AS treatment. A comprehensive literature review in this field is also carried out.

Patients and methods: We report the case of a 56-years-old man with radiological appearance of an 11 cm poor vascularised left renal mass. The pre-operative imaging ruled out distant metastases and inferior vena cava thrombosis. Thus, after radioembolization, we performed a transperitoneal open radical nephrectomy with regional lymphadenectomy with the removal of the middle portion of the ileo-psoas muscle, followed by two lines of adjuvant chemotherapy. We analysed all the papers concerning primary kidney AS until December 2018.

Results: Estimated intraoperative blood loss was 200 mL with an operative time of 100 minutes. No postoperative complications were recorded, with the patient discharge in the 8th postoperative day. The pathological assess-

ment showed a pT3a N0, M0 tumour compatible with AS of the kidney. An immune-histochemical study showed a vascular positive for CD31, CD34, Fli-1 with a Ki-67/Mib 1 of 50%. One month after surgery the patient began adjuvant chemotherapy with gemcitabine. After 45 days from surgery, a Computed Tomography scan showed lung and liver metastases with disease relapse in the left kidney lodge. The response to the first-line treatment was excellent, unlike the second-line, encountering a chemo-refractory disease. The cancer-specific survival was of 15 months. We included 66 cases in our review.

Conclusion: This is the first case of treatment of kidney AS performed at our Institute. Our findings added new information about the unclear biology and progression of this subset of tumours, demonstrating an abysmal prognosis.

Keywords: Vascular Tissue Neoplasms, Sarcoma, Kidney, Nephrectomy, Recurrence, Antineoplastic Agents, Local neoplasm recurrence, Prognosis, Treatment Failure

1 Introduction

Angiosarcoma (AS) is a rapid growth tumour of endothelial origin, which accounts for less than 2% of soft tissue sarcomas [1]. Most cases happen in older white men with an extremely high mortality rate mainly due to distant metastasis at the time of diagnosis or shortly afterwards. According to the World Health Organization (WHO), mean survival of 7.7 months was met [2].

Endothelial cells are considered the source of AS, but an origin from circulating stem cells recruited from bone marrow or extra-medullary hematopoiesis is argued [3, 4]. The skin accounts for approximately one-third of cases, especially in the head and neck region or the extremities [5]. Regardless of the primary organ affected, the five years overall survival rate is estimated to be 10-35%, with

*Corresponding author: **Morena Turco**, Department of Surgical and Biomedical Sciences, Urologic Clinic, University of Perugia - S.M. della Misericordia Hospital, P.le Menghini 1, 06132, Perugia, Italy, Tel +39 0755783898, Fax +39 0755784416, Email: dr.morenaturco@gmail.com

Andrea Boni, Giovanni Cochetti, Emanuele Lepri, Jacopo Adolfo Rossi De Vermandois, Michele Del Zingaro, Roberto Cirocchi, Ettore Mearini, Department of Surgical and Biomedical Sciences, Urologic Clinic, University of Perugia, University Hospital of Perugia, Perugia, Italy

Angelo Sidoni, Guido Bellezza, Department of Experimental Medicine, Section of Anatomic Pathology and Histology, Perugia Medical School, University of Perugia, Perugia, Italy

Andrea De Giglio, Department of Experimental Medicine, Section of Oncology, University of Perugia, Perugia, Italy

metastases found commonly in the lungs, liver, and bone, because of early hematogenous dissemination [6].

The bulk of the related literature describes the origin in a healthy kidney as a site of uncommon primary occurrence, reporting only a case of primary AS associated with a renal angiomyolipoma [7]. Some pathological conditions were listed as predisposing factors, but no direct causal relationship was ever demonstrated [8-10], as well as vinyl chloride, thorium dioxide, or radiation exposition [9]. The role of some genes involved in the receptor protein tyrosine kinase pathway was recently described [11].

The radiological diagnosis of this neoplasm is quite challenging because of the various overlapping characteristics with other tumoural subtypes. Thus, pathological examination with immune-histochemical findings remains essential. The surgical approach seems to ensure the more significant advantage in terms of prognosis, with adjuvant radio- and chemotherapy proposed to improve the cancer-specific survival, even if no standard treatment can be still set. However, in advanced renal disease, the role of surgery is still debated, mainly due to the significant morbidity and the development of effective adjuvant systemic therapies.

This study aimed to describe the first case of AS with extensive necrosis occurring in our Institute, interesting the left kidney. The follow-up was of 15 months until the patient died of the disease. In an attempt to identify prognostic factors and optimal treatment strategy, we also performed a comprehensive literature review, thus improving the knowledge about the aggressive behaviour of this tumour.

2 Material and methods

To provide helpful information to treat our case, we searched the published papers with the terms of ‘primary angiosarcoma of the kidney’ and ‘primary renal angiosarcoma’ in PubMed, Scopus, Google Scholar, and Embase databases, without language limitation. All articles and case reports of primary AS of the kidney until December 2018 were included. We obtained clinical and pathological data, including maximum tumour dimension measured in centimetres, laterality, and immune-histochemical expression of the tumour cells.

Informed consent has been obtained from patient included in this study.

Ethical approval: The research related to human use has been complied with all the relevant national regulations, institutional policies and in accordance the tenets of the Helsinki Declaration.

3 Case report

A 56-years-old male patient presented to the “Santa Maria della Misericordia” Hospital (Perugia, Italy) with left flank pain. An abdominal ultrasound scan detected a mass in the middle third of the left kidney measuring 8 x 10 cm, toward the lower pole, relatively round shaped. A whole-body Computed Tomography (CT) scan confirmed the presence of 11 cm lower pole mass in the left kidney. It appeared poorly vascularized by the appearance of large central collapsed area with signs of the infiltration of perirenal fat and perirenal band and various small lymph nodes under centimetres at the level of the mesenteric fan (Figure 1). The rapid peripheral enhance-wash-out of the contrast agent in the early arterial phase suggested a

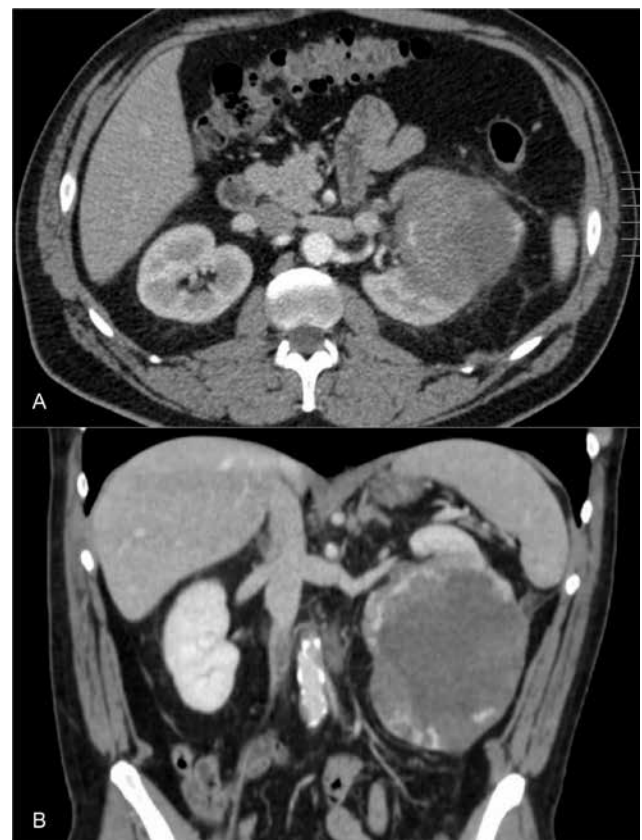


Figure 1: Preoperative computed tomography (ct) scan (a: axial reconstruction; b: coronal reconstruction) showing a mass with a poor vascularization and a collapsed area in the lower pole of the left kidney.

Renal Cell Carcinoma (RCC). No signs of the infiltration of the arterial-venous vascular peduncle or distant metastases were detected, confirmed after that by a bone scan.

The patient presented a single preoperative episode of macroscopic hematuria after diagnostic imaging. One day before surgery, we performed a left renal artery catheter embolisation using a Haemostatic Absorbable Gelatin Sponge (Spongostan, Ethicon™, Somerville, NJ, USA) and polyvinyl alcohol to decrease intraoperative bleeding risk. Then the patient underwent open radical nephrectomy with hilar and para-aortic lymph node dissection made by an expert urologist surgeon (EM) [12-14]. We removed the perirenal fat tissue, the ipsilateral adrenal gland, a 25 mm tract of the ureter, and the middle portion of the ileo-psoas muscle.

According to our review, radical nephrectomy is the most effective treatment for primary AS (Table 1); surgery was not listed as primary treatment in only 2 cases [15, 16].

4 Results

Estimated intraoperative blood loss was 200 mL and operative time was 100 minutes. The hospital stay was eight days long. Seven days after surgery, serum creatinine and eGFR were 0.98 mg/dL and 81 mL/minute, respectively; after three months, these parameters were the same. No postoperative complications occurred. The surgical specimen consisted of the entire left kidney, weighing 1,080 g and measuring 16 x 11.5 x 7 cm with a portion of the striated muscular belly of ileo-psoas, measuring 3.6 x 2.5 cm. The visible appearance of the solid tumour, located in the lower middle third of the kidney, was a cavitated hemorrhagic necrotising mass of about 14 x 9 cm (Figure 2). Specimens were fixed in 10% formalin, embedded in paraffin wax, sectioned at four μ m, and stained with hematoxylin and eosin. Histopathological examination showed vasoformative areas with ramifying channels lined by atypical endothelial cells together with more solid areas lacking vasoformative and composed by high-grade spindle-shaped cells with large hyperchromatic nuclei and prominent nucleoli (Figure 3a). The psoas muscle tissue, surgical margins, ureter, renal artery and vein, and left para-aortic lymph nodes did not appear infiltrated by the tumour. The immune-histochemical study showed strongly and diffusely positive staining for CD31 (Figure 3b), CD34, Fli-1, and remained harmful for pan-cytokeratin, MelanA, HMB45, PGM1, PAX8, GATA3, CD10, race-mase, p63, smooth muscle actin, desmin, HHV8; Ki-67/Mib 1:50%. These findings indicated that the tumour was

an AS of the kidney. Ipsilateral adrenal adenoma was also detected.

After 45 days from the surgical procedure, the patient developed hemoptysis. A total body CT scan was then performed with the evidence of a nodular mass of about 3 cm in the left kidney lodge (Fig. 4) and at the level of the left parietal-colic ligament, both showing contrast enhancement after administration of contrast medium. Furthermore, it showed several nodular opacities of the lungs with ground glass opacity (Fig. 5), and multiples hypodense liver lesions (Fig. 6), suggestive of distant metastases. Therefore, the patient underwent bronchoscopy with bioptic samples. The histological report was negative for neoplastic proliferation. In some macrophages, there was the presence of hemosiderin.

We presented the case within the Italian Rare Cancer Network (IRCEN), and the patient started first-line chemotherapy with Gemcitabine (1000 mg/mq, day 1-8-15, IV every 21 days) after two months from the surgical procedure, followed by an immediate clinical improvement after the first cycle. The CT scan evaluation performed three months later, showed a brilliant partial response according to the Response Evaluation Criteria in Solid Tumors (RECIST) 1.1 criteria, [17] namely with an almost complete abdominal response and a significant reduction of several lung lesions. A re-assessment CT scan, performed in May 2018, after 11 cycles of therapy, pointed out a severe lung and soft tissue progression. Thus, the patient started second-line chemotherapy with Olaratumab (15 mg/Kg, day 1-8) and Doxorubicin (75 mg/kg, day 1-8) given intravenously every 21 days. Unfortunately, a fast-worsening disease occurred with an impressive progression in lungs, liver, and soft-tissues, confirmed by a total body CT scan assessed after three cycles. The chemotherapy regimen was switched to a weekly Paclitaxel schedule (80 mg/mq). At last, the patient died after four cycles due to hepatic insufficiency. The flow-chart reports the clinical sequence of the patient.

5 Discussion

Over the past few years, significant concerns emerged about the standard treatment of AS, mainly due to the advances in the understanding of its aggressive behaviour [1]. AS unusually harbours from the kidney, and it was first described by Prince in 1942 [18], after a clear definition of this heterogeneous group of the tumour was set [19, 20]. Numerous overlapping radiological characteristics could be observed in particular with RCC [14, 21, 22].

Table 1: Literature review of primary kidney angiosarcoma

Author	Age (yy)	Sex	Side	Clinical presentation	Size (cm)	Mets	Sites (initial and subsequent mets)	Treatment	Follow-up (months)	Outcome
Qayyum <i>et al.</i> [14]	86	M	R	wl, fatigue, dizziness	12.3	Yes	Liver, lungs	Palliative (patient's wish)	NA	NA
Zhang <i>et al.</i> [39]	52	M	L	fp, left leg pain	8	Yes	Liver, bone	Nephr	NA	NA
Liu <i>et al.</i> [38]	75	M	R	hematuria	4	No	No	Nephr, RT	6	NED
Brown <i>et al.</i> [43]	68	M	R	NA	24	Yes	Liver	NA	6	DOD
Brown <i>et al.</i> [43]	64	M	L	NA	30	No	No	NA	11	DOD
Brown <i>et al.</i> [43]	71	M	L	NA	10	Yes	Peritoneal and periaortic LN	NA	1	DOD
Brown <i>et al.</i> [43]	72	M	L	NA	NA	No	No	NA	NA	NA
Brown <i>et al.</i> [43]	29	F	L	NA	3.7	NA	NA	NA	1	DOD
Brown <i>et al.</i> [43]	62	M	NA	NA	NA	NA	NA	Nephr	NA	NA
Brown <i>et al.</i> [43]	67	M	R	NA	NA	NA	NA	Nephr	NA	NA
Brown <i>et al.</i> [43]	95	M	R	NA	15.5	NA	NA	Nephr	2	DFUD
Cason <i>et al.</i> [18]	46	M	L	fp, wl	13	No	Bone, liver, abdominal soft tissue	Nephr, chemotherapy, RT	10	DOD
Allred <i>et al.</i> [44]	67	M	R	fp, hematuria	13	Yes	Lungs, liver	Nephr, chemotherapy	3	DOD
Peters <i>et al.</i> [45]	74	M	L	wl	19	Yes	Lungs, liver, abdominal wall, head	Nephr	2	DOD
Prince <i>et al.</i> [17]	51	M	L	fp, hematuria	10	No	No	Nephr, RT	NA	A&W
Sabharwal <i>et al.</i> [40]	67	M	L	loin pain, wl, loss of appetite	13	Yes	Spleen	Nephr, chemotherapy	1	NA
Chaabouni <i>et al.</i> [46]	59	M	R	fp, hematuria	6.5	No	No	Nephr	1	DOD
López Cubillana <i>et al.</i> [47]	72	M	R	hematuria	13	No	Bone and lung	Nephr, chemotherapy	5	DOD
Singh <i>et al.</i> [33]	83	M	L	hematuria	13	No	No	NA	NA	NA
Askari <i>et al.</i> [48]	24	M	R	hematuria, ureteric obstruction	9	No	No	Nephr	4	DOD
Douard <i>et al.</i> [49]	60	M	R	NA	NA	Yes	Bone, lung	Nephr	3	DOD
Terris <i>et al.</i> [36]	47	M	L	fp	19	Yes	Diaphragm, renal artery, liver and bone	Nephr, RT	10	DOD
Zenico <i>et al.</i> [50]	56	M	L	incidental finding	20	No	No	Nephr	4	DOD
Desai <i>et al.</i> [51]	54	M	L	fp, hematuria	21	No	Bone	Nephr, chemotherapy	4	DOD
Johnson <i>et al.</i> [15]	50	M	L	fp, hemoptysis	9	Yes	Liver, lung	Rapid deterioration	NA	DOD
Kern <i>et al.</i> [52]	69	M	L	fp, wl, hematuria	26	Yes	Lung	Nephr	1.5	DOD
Kern <i>et al.</i> [52]	52	M	L	hematuria	8	Yes	Lung	Nephr	3	DOD
Fukunaga <i>et al.</i> [32]	61	M	L	incidental finding	8	No	Liver, bone and retroperitoneum	Nephr	13	DOD
Adjiman <i>et al.</i> [53]	36	M	R	hemoptysis, fp, fever	10.5	Yes	Chest wall, skin	Nephr	NA	DOD

Table 1 continued: Literature review of primary kidney angiosarcoma

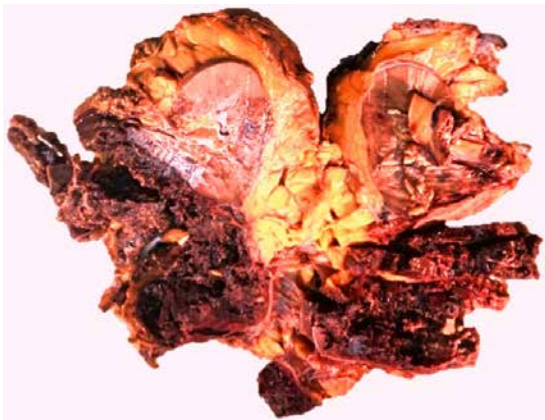Author	Age (yy)	Sex	Side	Clinical presentation	Size (cm)	Mets	Sites (initial and subsequent mets)	Treatment	Follow-up (months)	Outcome
Papadimitriou et al.[9]	68	M	L	fp, dysuria, hematuria	10	No	No	Nephr	NA	A&W
Tsuda et al.[54]	77	M	L	hematuria, renal failure	10	No	Retroperitoneum, liver	Nephr	21	DOD
Leggio et al.[34]	60	M	L	post-trauma abd pain	12	No	Spleen, peritoneum	Nephr	8	DOD
Mordkin et al.[55]	75	M	L	fever, wl	19	Yes	Spleen, bone, liver, soft tissue, oral cavity	Nephr, chemotherapy, S	NA	NA
Akkad et al.[35]	58	M	R	incidental finding	4.5	No	No	Nephr	30	NED
Cerilli et al.[56]	67	M	R	fp, hematuria	12.5	Yes	Renal vein	Nephr, RT	6	DOD
Aksoy et al.[57]	55	M	L	abd pain, rupture with retroperitoneal hematoma	13	No	No	Nephr, S	3	DOD
Hiratsuka et al.[19]	59	F	R	hematuria	4.5	No	No	Nephr	29	NED
Aydogdu et al.[58]	77	M	L	NA	NA	NA	NA	Nephr	NA	NA
Martinez-Pineiro et al.[37]	66	M	L	abd pain, anorexia, asthenia	11.5	No	Bone, liver, lungs	Nephr	5	DOD
Lee et al.[28]	63	M	NA	NA	NA	NA	NA	NA	NA	NA
Berretta et al.[59]	67	M	NA	NA	NA	NA	NA	Nephr, chemotherapy	NA	NA
Souza et al.[60]	75	M	L	wl, fp, hematuria	15	No	No	Nephr	NA	DFUD
Costero-Barrios et al.[61]	71	M	L	hematuria, fp	18	No	Liver and retroperitoneum	Nephr, chemotherapy, RT	12	Recurrence
Grapsa et al.[62]	65	M	R	fever, fatigue, dyspnea	13.8	Yes	Liver, lung	NA	NA	NA
Carnero Lopez et al.[22]	29	F	L	Hemoptysis	11	Yes	Lungs	Nephr, chemotherapy	5	DOD
Sesar et al.[63]	65	M	L	incidental finding	4.5	NA	NA	Nephr, ureterectomy	NA	NA
Pauli et al.[63]	57	M	L	hemoptysis	15	Yes	Lungs, bone	Nephr, RT	2	DOD
Yoshida et al.[64]	78	M	L	fp	18	Yes	Liver, bone	Nephr, immunotherapy	13	DOD
Juan et al.[65]	81	F	NA	hematuria	5	Yes	Liver, bone	Nephr, chemotherapy, RT	9	DOD
Xuan et al.[66]	63	M	L	pain and costal swelling	10	NA	NA	Nephr	NA	NA
Yau et al.[67]	38	F	R	hematuria, bone pain	13	Yes	Bone, LN	Nephr, chemotherapy, RT	3	DOD
Garmendia et al.[68]	51	M	NA	NA	NA	NA	NA	NA	NA	NA
Nguyen et al.[69]	53	M	L	hematuria, fp	7	Yes	Lung	Nephr, chemotherapy	18	DOD
Limmer et al.[70]	48	M	L	fp	10	No	Lung, soft tissue, muscle	Nephr	1	DOD
Matter et al.[71]	62	M	L	fp, abd mass	18	No	Lung	Nephr, chemotherapy, RT	18	DOD
Sanyal et al.[72]	30	M	NA	NA	NA	No	No	Nephr, RT	24	DOD
Testa et al.[73]	NA	NA	NA	NA	NA	NA	NA	NA	NA	NA
Yamamoto et al.[74]	68	M	R	incidental finding	7	No	No	Nephr, RT	19	NED

Table 1 continued: Literature review of primary kidney angiosarcoma

Author	Age (yy)	Sex	Side	Clinical presentation	Size (cm)	Mets	Sites (initial and subsequent mets)	Treatment	Follow-up (months)	Outcome
Rüb et al.[75]	59	M	L	hematuria, wl	18	No	Lungs, liver	Nephr, chemotherapy	12	AWD
Celebi et al.[76]	57	M	R	fp, hematuria	14	No	Lungs, pelvis	Nephr, chemotherapy	13	DOD
Li et al.[77]	69	F	L	NA	NA	NA	NA	NA	NA	NA
Witczak et al.[78]	44	F	NA	hematuria	NA	NA	NA	Nephr	NA	NA
Cuadra-Urteaga et al.[79]	44	M	R	hematuria	7.5	No	No	Nephro-ureterectomy	2	DOD
Iannaci et al.[26]	56	M	L	lower back pain and 4 hematuria	4	Yes	Lungs	Nephr	NA	DOD
Su[80]	53	F	R	right lower abd pain	8.5	No	Local advanced	Nephr, chemotherapy	NA	DFUD
Gourley et al.[10]	NA	M	R	acute right fp	12.5	No	No	Nephr	NA	NA
Guan et al.	64	F	L	fp, fatigue, wl	18	No	Local advanced	Mass excision, chemotherapy	4	DOD

Notes:

Abbreviations: Mets, metastases; dx, diagnosis; M, male; F, female; L, left; R, right; NA, not available; abd, abdominal; fp, flank pain; wl, weight loss; LN, lymph node; Nephr, Nephrectomy; NED, no evidence of disease; DFUD, died from unrelated disease; AWD, alive with disease; DOD, died of disease; RT, radiotherapy; S, splenectomy; A&W, alive and well.

**Figure 2:** Operative specimen demonstrating.

Nowadays, we noted a prevalence of incidental diagnosis in the RCC, while the most common clinical presentation of AS includes macroscopic hematuria (81%), flank pain (38%), or a palpable renal mass (31%) [23]. Its typical histopathological features are the presence of aberrant vascular structures with malignant endothelial cells.

Primary renal AS has a poor prognosis with a high mortality rate mainly due to local recurrence and an early hematogenous spread. Metastases are usually found at the time of diagnosis or develop within a couple of months after surgery. Thus, the absence of detectable metastases

at the time of operation does not improve the survival rate, with a minimal number of patients surviving more than one year [8].

Several substances such as thorium dioxide (Thoro-trast®) for cerebral angiography, insecticides, and vinyl chloride were linked to the induction of hepatic AS [6, 24-26]. Conditions associated with the development of AS were radiotherapy, filariasis, chronic lymphedema of any cause (Stewart-Treves syndrome), and von Recklinghausen's disease, with a recently reported case of AS arising in schwannoma of the kidney [5, 27]. Another example was said to origin in a polycystic kidney [10]. However, none of these risk factors has been proven to have a direct causal relationship with renal AS. The role of some genes, such as p53, VEGF, Ras, Myc, and MDM2, have been explored but their interaction in the development of tumoral phenotype is far to be found [11, 28].

Even if no stable radiological features exist for renal AS, in case of enhancing hypervascular rim and a non-enhancing centre with fast wash-out of the contrast medium, a differential diagnosis with angiomyolipoma shall be done. After that, an advanced RCC and carcinosarcoma should be ruled out [14, 29]. In the latter case the interphase sarcomatous component and carcinomatous one result sharp. In the literature, only one instance of a

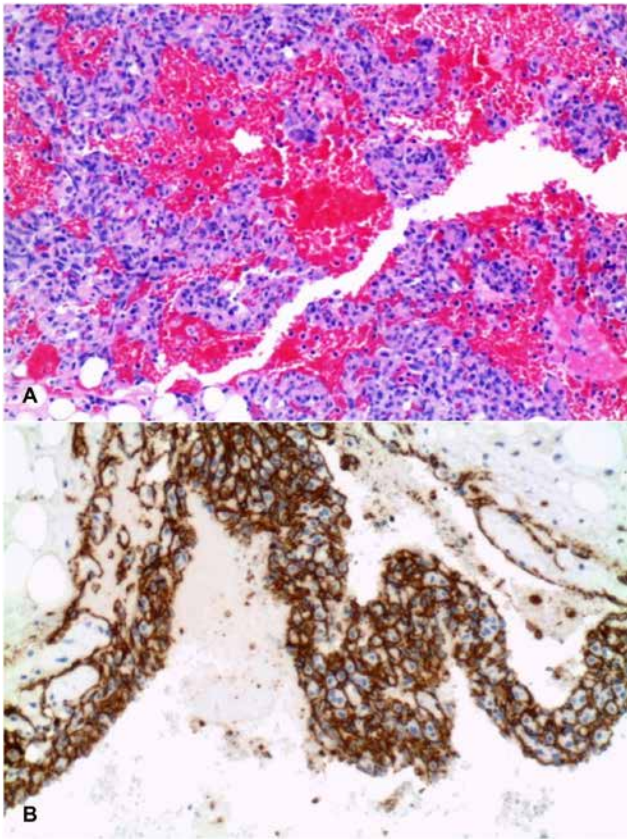


Figure 3: Angiosarcoma (as) of the kidney. (A) clusters of atypical spindle-shaped cells forming irregular vascular channels and rudimentary lumen formation (haematoxylin-eosin, 200x); (b) immunostain for cd31 shows intense staining of most as cells (200x).

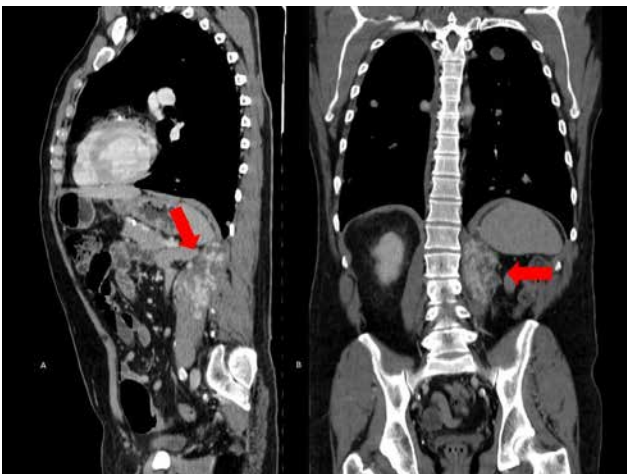


Figure 4: Axial (a) and coronal (b) reconstruction on ct scan showing a local recurrence of tumoral tissue (red arrow) in the left kidney lodge, alongside the parieto-colic ligament.

Von-Hippel-Lindau negative patient exists, showing the presence of minute clear cell carcinomas between AS and non-tumoral renal parenchyma [30]. To our knowledge, one case of fine-needle aspiration cytology with the appli-

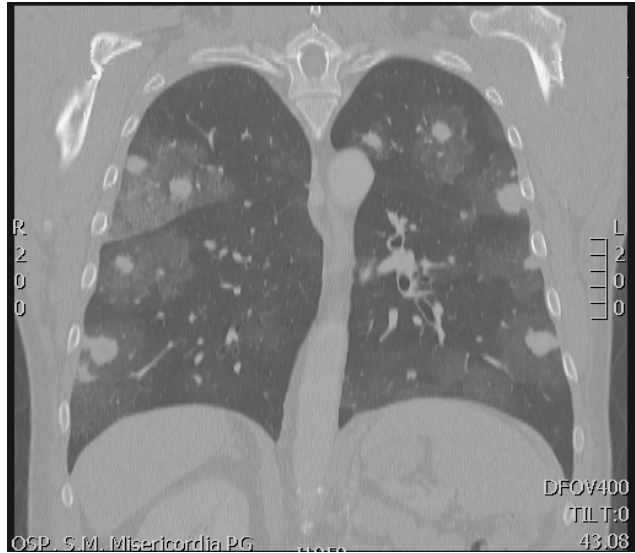

Figure 5: CORONAL CT SCAN showing several nodular opacities of the lungs with ground glass opacity and tree-in-bud signs

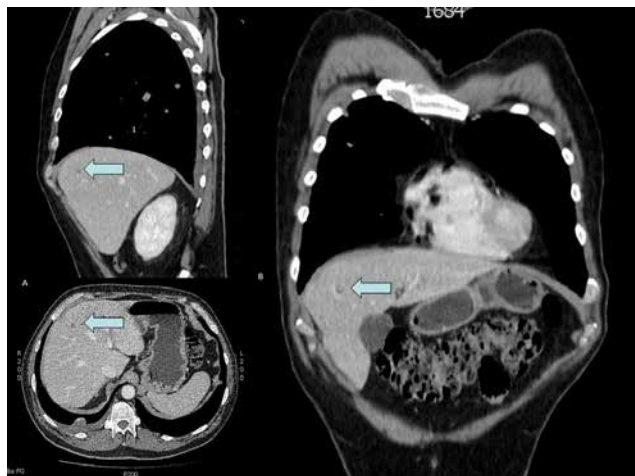


Figure 6: AXIAL (A) and CORONAL (B) RECONSTRUCTION on CT SCAN showing multiples hypodense liver lesions. The arrow point the biggest one of almost 10 mm of diameter.

cation of immune-histochemical analysis was reported in an 83-year-old man, referred to the oncologists for primary chemotherapy [31].

The demonstration of endothelial cell line molecules, like CD31, CD34, and human hematopoietic progenitor cell antigen, was accounted with high specificity and sensitivity [32]. Furthermore, the presence of numerous anastomosing small vessels enveloped by polymorphic tumour cells was probably the consequence of the non-hypoxia induced intratumoral activation with an autonomous, non-dependent by Vascular Endothelial Growth Factor (VEGF) tyrosine kinase receptor activation [33]. Cavernous hemangioma-like, sinusoidal and papillary arrangements might also arise in the tumour [30].

February 2017

56-years-old man with left flank pain

a. **Abdominal US:** 8x10cm-mass of the middle third of left kidney.
 b. **Contrast-enhanced CT:** 11cm-solid mass of the lower pole of the left kidney, with poorly vascularization. No signs of arterial-venous peduncle infiltration or distant metastases (**Fig. 1**)

Suggestion of RCC at CT scan (*rapid peripheral wash-out of contrast medium during early arterial phase*)

March 2017

1. Embolization of the left renal artery.
 2. Open Radical Nephrectomy, hilar and para-aortic lymph node dissection, removal of perirenal fat tissue, adrenal gland, portion of ureter and ileo-psoas muscle.

Histopathological assessment:
 1. *Macroscopically:* 14x9 cm-cavitated hemorrhagic necrotizing mass. (**Fig. 2**)
 2. *Microscopically:* Atypical endothelial cells and spindle-shaped cells. No infiltration of surgical margins, psoas-muscle, ureter, vascular peduncle, lymph nodes.
 3. *Immunohistochemistry (Fig. 3):* positive staining for CD31, CD34, Fli-1.

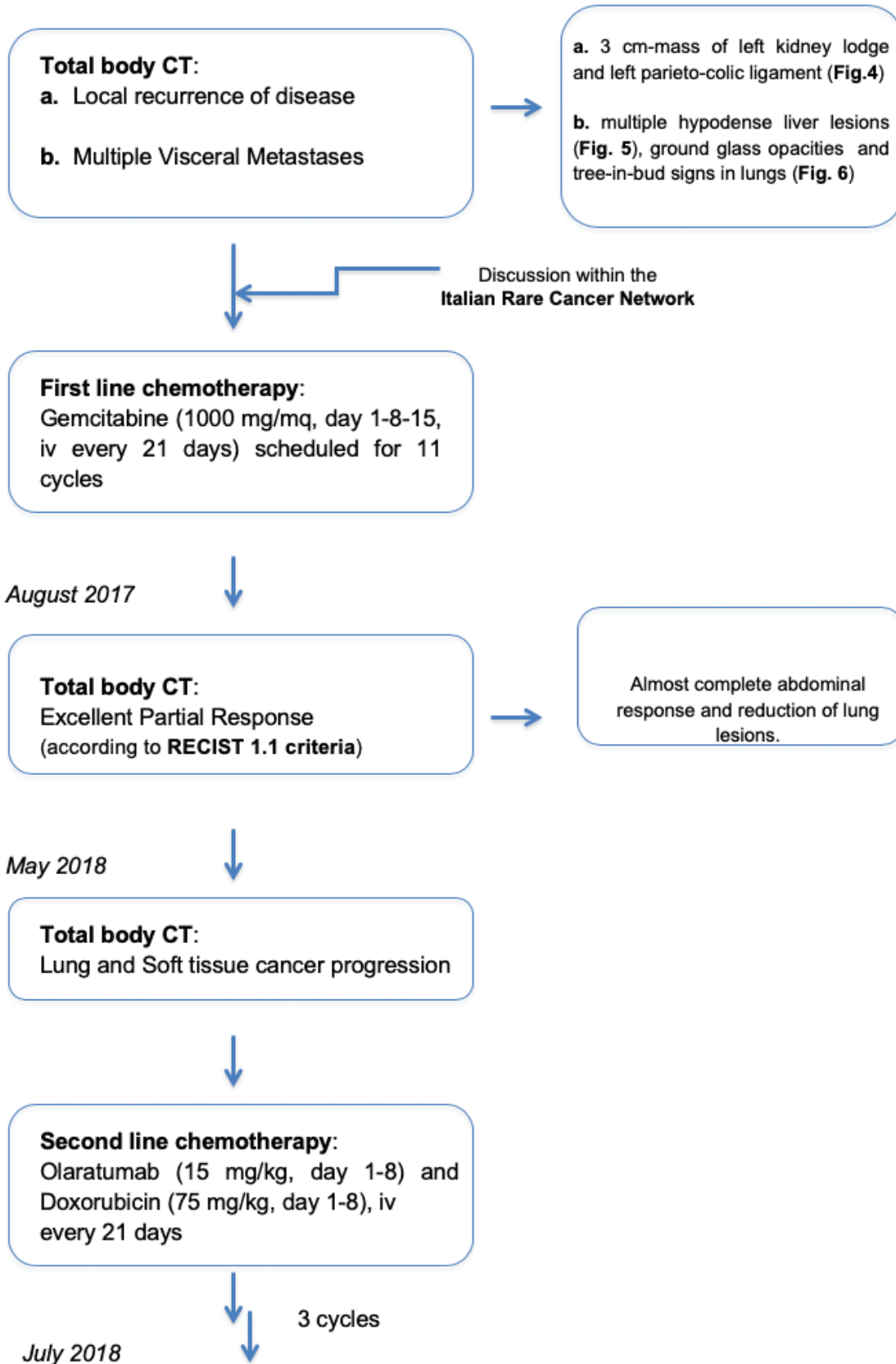
No postoperative complication.
 Discharge: postoperative day 8.

Diagnosis of
**Primary Kidney
 AngioSarcoma**

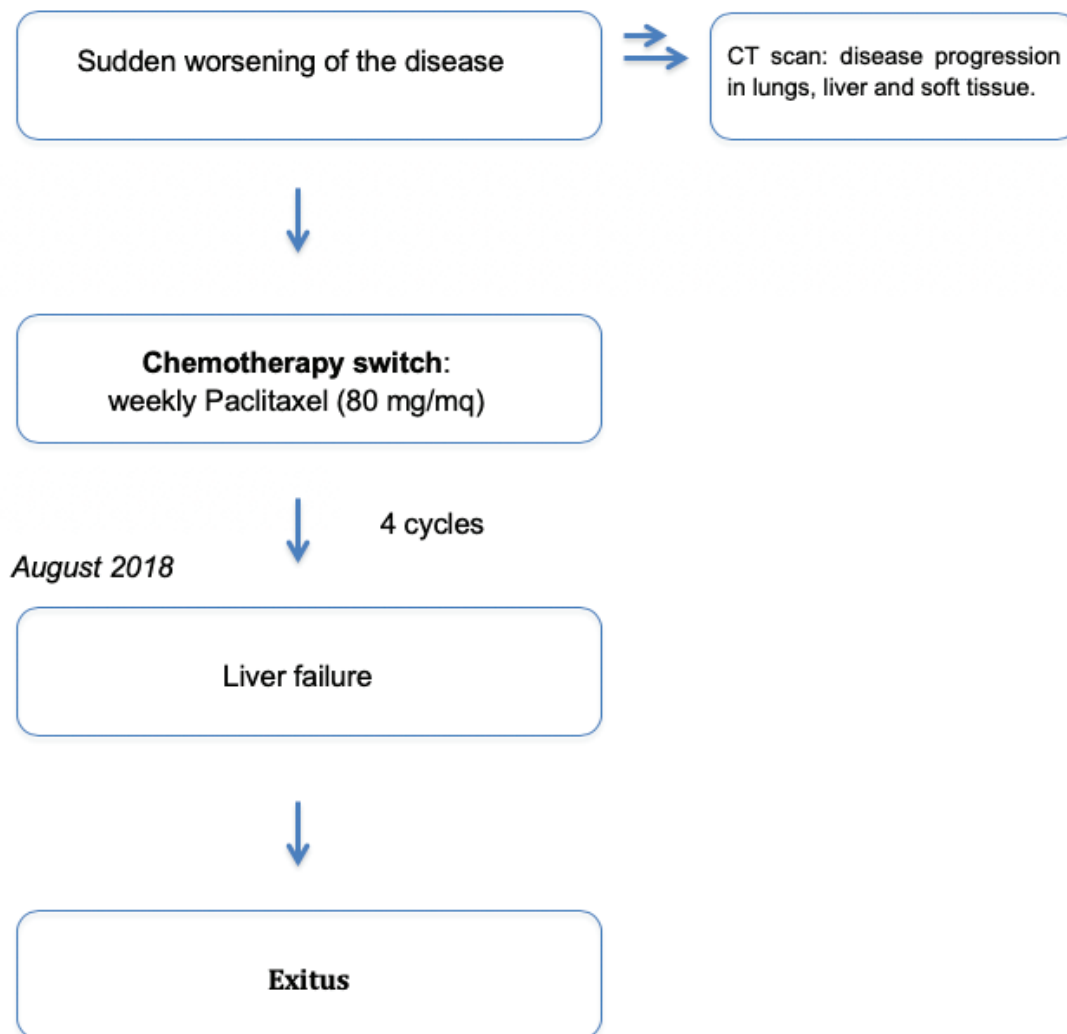
May 2017

Episode of **Hemoptysis**

Clinical flow-chart reporting main uro-oncological proceedings



Clinical flow-chart reporting main uro-oncological proceedings continued



Clinical flow-chart reporting main uro-oncological proceedings continued

Regarding the treatment of the soft tissue sarcomas, it always involves radical surgery, as margin negativity is crucial for the cure. The role of chemotherapy and radiotherapy remains controversial, even if the latter has demonstrated to improve local control of the disease [34].

The present is an exceptional primary case of AS of the kidney, which updates the limited literature in this field. Beyond its rarity, the lack of information available makes this tumour very difficult to treat. This case occurred in the left kidney of a 56-year-old white man, free of genetic syndromes. He underwent cerebral angiography with thorium dioxide for a cerebrovascular study about thirty years before AS occurrence.

The disease developed insidiously, starting with flank pain, gross hematuria one week before surgery, and weight loss (10 kg in 15 days). Its clinical presentation is in line

with that expected by previous reports. Metastases were not detectable at the preoperative CT scan, even if one was suspected in ipsilateral adrenal gland together with infiltration of the psoas muscle. These acquisitions did not stop us from performing a primary surgical strategy to remove all the pathologic tissue since it was demonstrated to be the most effective treatment approach [35]. Based on the histopathological analysis, we found the presence of a benign adenoma, without the involvement of the adrenal gland and the absence of infiltration of the psoas muscle.

The endothelial nature of the neoplastic cells in our case was verified by diffuse positive immune-histochemical staining for the highly sensitive vascular marker CD-34 in 100% of the tumour cells [9, 35]. The raising proliferative nature of the tumour is suggested by the Ki-67 index reported to be 30% [36], 40% (9) [37], and >80% [38]

respectively. In our specimen, the Ki-67 index was about 50%, and we now confirm it to indicate a high aggressiveness of this tumour.

After the patient was referred to the oncologist, he performed a two months follow-up CT scan showing local recurrence in the kidney lodge measuring 3 cm and peritoneal, liver, and lung metastases. Although the first line chemotherapy regimen of choice for metastatic AS included anthracyclines plus ifosfamide, often it can be difficult to administer for a suboptimal performance status (PS ECOG 3-4) or advanced age [17].

In this case, the fast-worsening clinical presentation induced to use gemcitabine as the first line, following a retrospective experience collected by the IRCN [39]. As above mentioned, the patient presented an excellent response to the treatment with good progression-free survival of 12 months, but the following line of therapy did not determine any effect, encountering a chemo-refractory disease with a cancer-specific survival of 15 months.

6 Conclusion

Primary AS of the kidney represents a rare variant of renal parenchymal cancer with a high potential of malignancy, profoundly affecting cancer-specific survival. Our findings add new information about the biology and progression of these neoplasms in the attempt to achieve the definition of a standard approach to this tumour.

Acknowledgements: The authors want to thank all the Urologic Clinic and Section of Oncology for patient's care and all the Section of Anatomic Pathology and Histology of the University Hospital of Perugia for its fundamental contribution in histopathological examination of specimens. The authors are grateful to the patient's family, in his loving memory.

Author contributions: AB, EM, GC, MT, and RC were responsible for data collection and literature review, ADG and JARDV for oncologic data collection, GB, EL, and AS for acquisition of histopathological data. MDZ provide an entire manuscript formal review. All authors had full access to all the study data and took part in the designing and drafting of the work. All of them reviewed the entire manuscript and take responsibility for the accuracy of the content.

Disclosure: None of the authors reports conflicts of interest in this work.

References

- [1] Temple WJ, Bramwell V, Eisenhauer E, Jenkin RD, Langer F, Worth AJ: Guidelines for the surgical management of soft-tissue sarcoma. Report of the Canadian Sarcoma Group. *Canadian Journal of surgery Journal canadien de chirurgie* 1988, 31(6):410-412
- [2] Nachman J, Simon MA, Dean L, Shermeta D, Dawson P, Vogelzang NJ: Disparate histologic responses in simultaneously resected primary and metastatic osteosarcoma following intravenous neoadjuvant chemotherapy. *Journal of clinical oncology : official journal of the American Society of Clinical Oncology* 1987, 5(8):1185-1190
- [3] Young RJ, Brown NJ, Reed MW, Hughes D, Woll PJ: Angiosarcoma. *The Lancet Oncology* 2010, 11(10):983-991
- [4] Cohen SM, Storer RD, Criswell KA, Doerrer NG, Dellarco VL, Pegg DG, Wojcinski ZW, Malarkey DE, Jacobs AC, Klaunig JE et al: Hemangiosarcoma in rodents: mode-of-action evaluation and human relevance. *Toxicological sciences : an official journal of the Society of Toxicology* 2009, 111(1):4-18
- [5] Cui L, Zhang J, Zhang X, Chang H, Qu C, Zhang J, Zhong D: Angiosarcoma (Stewart-Treves syndrome) in postmastectomy patients: report of 10 cases and review of literature. *International journal of clinical and experimental pathology* 2015, 8(9):11108-11115
- [6] Mark RJ, Poen JC, Tran LM, Fu YS, Juillard GF: Angiosarcoma. A report of 67 patients and a review of the literature. *Cancer* 1996, 77(11):2400-2406
- [7] Gourley E, Digman G, Nicolas M, Kaushik D: Primary renal angiosarcoma. *BMJ case reports* 2018, 2018
- [8] Oskrochi Y, Razi K, Stebbing J, Crane J: Angiosarcoma and Dialysis-related Arteriovenous Fistulae: A Comprehensive Review. *European journal of vascular and endovascular surgery : the official journal of the European Society for Vascular Surgery* 2016, 51(1):127-133
- [9] Omiyale AO: Clinicopathological features of primary angiosarcoma of the kidney: a review of 62 cases. *Translational andrology and urology* 2015, 4(4):464-473
- [10] Papadimitriou VD, Stamatou KN, Takos DM, Adamopoulos VM, Heretis IE, Sofras FA: Angiosarcoma of kidney: a case report and review of literature. *Urol J* 2009, 6(3):223-225
- [11] Styring E, Seinen J, Dominguez-Valentin M, Domanski HA, Jonsson M, von Steyern FV, Hoekstra HJ, Suurmeijer AJ, Nilbert M: Key roles for MYC, KIT and RET signaling in secondary angiosarcomas. *British journal of cancer* 2014, 111(2):407-412
- [12] Cochetti G, Barillaro F, Boni A, Del Zingaro M, Ettore M: Robot assisted laparoscopic excision of a paraganglioma: new therapeutic approach. *International braz j urol : official journal of the Brazilian Society of Urology* 2014, 40(2):279-280
- [13] Cochetti G, Barillaro F, Boni A, Mearini E: Immediate Radical Cystectomy for Massive Bleeding of Bladder Cancer. *BioMed research international* 2015
- [14] Boni A, Cochetti G, Ascani S, Del Zingaro M, Quadri F, Paladini A, Cocca D, Mearini E: Robotic treatment of oligometastatic kidney tumor with synchronous pancreatic metastasis: case report and review of the literature. *BMC surgery* 2018, 18(1):40

- [15] Qayyum S, Parikh JG, Zafar N: Primary renal angiosarcoma with extensive necrosis: a difficult diagnosis. *Case reports in pathology* 2014, 2014:416170
- [16] Johnson VV, Gaertner EM, Crothers BA: Fine-needle aspiration of renal angiosarcoma. *Archives of pathology & laboratory medicine* 2002, 126(4):478-480
- [17] Eisenhauer EA, Therasse P, Bogaerts J, Schwartz LH, Sargent D, Ford R, Dancey J, Arbuck S, Gwyther S, Mooney M *et al*: New response evaluation criteria in solid tumours: revised RECIST guideline (version 1.1). *Eur J Cancer* 2009, 45(2):228-247
- [18] Prince M: Concerning a Letter to Past Presidents of the California Medical Association and Reply thereto. *California and western medicine* 1942, 56(5):331
- [19] Cason JD, Waisman J, Plaine L: Angiosarcoma of kidney. *Urology* 1987, 30(3):281-283
- [20] Hiratsuka Y, Nishimura H, Kajiwara I, Matsuoka H, Kawamura K: Renal angiosarcoma: a case report. *Int J Urol* 1997, 4(1):90-93
- [21] Cochetti G, Puxeddu E, Del Zingaro M, D'Amico F, Cottini E, Barillaro F, Mearini E: Laparoscopic partial nephrectomy of thyroid cancer metastasis: case report and review of the literature. *OncoTargets and therapy* 2013, 6:355-360
- [22] Mearini E, Cochetti G, Barillaro F, Fatigoni S, Roila F: Renal malignant solitary fibrous tumor with single lymph node involvement: report of unusual metastasis and review of the literature. *OncoTargets and therapy* 2014, 7:679-685
- [23] Carnero Lopez B, Fernandez Perez I, Carrasco Alvarez JA, Lazaro Quintela ME, Lopez Jato C, Jorge Fernandez M, Gentil Gonzalez M, Vazquez Tunas L, Castellanos Diez J: Renal primary angiosarcoma. *Clinical & translational oncology : official publication of the Federation of Spanish Oncology Societies and of the National Cancer Institute of Mexico* 2007, 9(12):806-810
- [24] Popper H, Thomas LB, Telles NC, Falk H, Selikoff IJ: Development of hepatic angiosarcoma in man induced by vinyl chloride, thorotrast, and arsenic. Comparison with cases of unknown etiology. *The American journal of pathology* 1978, 92(2):349-376
- [25] Ho SY, Tsai CC, Tsai YC, Guo HR: Hepatic angiosarcoma presenting as hepatic rupture in a patient with long-term ingestion of arsenic. *Journal of the Formosan Medical Association = Taiwan yi zhi* 2004, 103(5):374-379
- [26] Alrenga DP: Primary angiosarcoma of the liver. Review article. *International surgery* 1975, 60(4):198-203
- [27] Iannaci G, Crispino M, Cifarelli P, Montella M, Panarese I, Ronchi A, Russo R, Tremitterra G, Luise R, Sapere P: Epithelioid angiosarcoma arising in schwannoma of the kidney: report of the first case and review of the literature. *World journal of surgical oncology* 2016, 14(1):29
- [28] Yang J, Kantrow S, Sai J, Hawkins OE, Boothby M, Ayers GD, Young ED, Demicco EG, Lazar AJ, Lev D *et al*: INK4a/ARF [corrected] inactivation with activation of the NF-kappaB/IL-6 pathway is sufficient to drive the development and growth of angiosarcoma. *Cancer research* 2012, 72(18):4682-4695
- [29] Pansadoro A, Cochetti G, D'amico F, Barillaro F, Del Zingaro M, Mearini E: Retroperitoneal laparoscopic renal tumour enucleation with local hypotension on demand. *World J Urol* 2015, 33(3):427-432
- [30] Fukunaga M: Angiosarcoma of the kidney with minute clear cell carcinomas: a case report. *Pathology, research and practice* 2009, 205(5):347-351
- [31] Singh C, Xie L, Schmechel SC, Manivel JC, Pambuccian SE: Epithelioid angiosarcoma of the kidney: a diagnostic dilemma in fine-needle aspiration cytology. *Diagnostic cytopathology* 2012, 40 Suppl 2:E131-139
- [32] Leggio L, Addolorato G, Abenavoli L, Ferrulli A, D'Angelo C, Mirijello A, Vonghia L, Schinzari G, Arena V, Perrone L *et al*: Primary renal angiosarcoma: a rare malignancy. A case report and review of the literature. *Urologic oncology* 2006, 24(4):307-312
- [33] Akkad T, Tsankov A, Pelzer A, Peschel R, Bartsch G, Steiner H: Early diagnosis and straight forward surgery of an asymptomatic primary angiosarcoma of the kidney led to long-term survival. *Int J Urol* 2006, 13(8):1112-1114
- [34] Terris D, Plaine L, Steinfeld A: Renal angiosarcoma. *American journal of kidney diseases : the official journal of the National Kidney Foundation* 1986, 8(2):131-133
- [35] Martinez-Pineiro L, Lopez-Ferrer P, Picazo ML, Martinez-Pineiro JA: Primary renal angiosarcoma. Case report and review of the literature. *Scand J Urol Nephrol* 1995, 29(1):103-108
- [36] Liu H, Huang X, Chen H, Wang X, Chen L: Epithelioid angiosarcoma of the kidney: A case report and literature review. *Oncology letters* 2014, 8(3):1155-1158
- [37] Zhang HM, Yan Y, Luo M, Xu YF, Peng B, Zheng JH: Primary angiosarcoma of the kidney: case analysis and literature review. *International journal of clinical and experimental pathology* 2014, 7(7):3555-3562
- [38] Sabharwal S, John NT, Kumar RM, Kekre NS: Primary renal angiosarcoma. *Indian journal of urology : IJU : journal of the Urological Society of India* 2013, 29(2):145-147
- [39] Stacchiotti S, Palassini E, Sanfilippo R, Vincenzi B, Arena MG, Bochicchio AM, De Rosa P, Nuzzo A, Turano S, Morosi C *et al*: Gemcitabine in advanced angiosarcoma: a retrospective case series analysis from the Italian Rare Cancer Network. *Ann Oncol* 2012, 23(2):501-508
- [40] Brown JG, Folpe AL, Rao P, Lazar AJ, Paner GP, Gupta R, Parakh R, Cheville JC, Amin MB: Primary vascular tumors and tumor-like lesions of the kidney: a clinicopathologic analysis of 25 cases. *The American journal of surgical pathology* 2010, 34(7):942-949
- [41] Allred CD, Cathey WJ, McDivitt RW: Primary renal angiosarcoma: a case report. *Human pathology* 1981, 12(7):665-668
- [42] Peters HJ, Nuri M, Munzenmaier R: Hemangioendothelioma of the kidney: a case report and review of the literature. *The Journal of urology* 1974, 112(6):723-726
- [43] Chaabouni A, Rebai N, Chabchoub K, Fourati M, Bouacida M, Slimen MH, Bahloul A, Mhiri MN: Primary renal angiosarcoma: Case report and literature review. *Canadian Urological Association journal = Journal de l'Association des urologues du Canada* 2013, 7(5-6):E430-432
- [44] Lopez Cubillana P, Martinez Barba E, Server Pastor G, Prieto Gonzalez A, Ferri Niguez B, Cao Avellaneda E, Lopez Lopez AI, Nicolas Torroalba JA, Rigabert Montiel M, Tornero Ruiz J *et al*: [Fatal evolution of a renal angiosarcoma]. *Archivos espanoles de urologia* 2004, 57(4):425-426

- [45] Askari A, Novick A, Braun W, Steinmuller D: Late ureteral obstruction and hematuria from de novo angiosarcoma in a renal transplant patient. *The Journal of urology* 1980, 124(5):717-719
- [46] Douard A, Pasticier G, Deminiere C, Wallerand H, Ferriere JM, Bernhard JC: [Primary angiosarcoma of the kidney: case report and literature review]. *Progres en urologie : journal de l'Association francaise d'urologie et de la Societe francaise d'urologie* 2012, 22(7):438-441
- [47] Zenico T, Saccomanni M, Salomone U, Bercovich E: Primary renal angiosarcoma: a case report and review of world literature. *Tumori* 2011, 97(4):e6-9
- [48] Desai MB, Chess Q, Naidich JB, Weiner R: Primary renal angiosarcoma mimicking a renal cell carcinoma. *Urologic radiology* 1989, 11(1):30-32
- [49] Kern SB, Gott L, Faulkner J, 2nd: Occurrence of primary renal angiosarcoma in brothers. *Archives of pathology & laboratory medicine* 1995, 119(1):75-78
- [50] Adjiman S, Zerbib M, Flam T, Brochard M, Desligneres S, Boissonnas A, Debre B, Steg A: Genitourinary tumors and HIV1 infection. *European urology* 1990, 18(1):61-63
- [51] Tsuda N, Chowdhury PR, Hayashi T, Anami M, Iseki M, Koga S, Matsuya F, Kanetake H, Saito Y, Horita Y: Primary renal angiosarcoma: a case report and review of the literature. *Pathology international* 1997, 47(11):778-783
- [52] Mordkin RM, Dahut WL, Lynch JH: Renal angiosarcoma: a rare primary genitourinary malignancy. *Southern medical journal* 1997, 90(11):1159-1160
- [53] Cerilli LA, Huffman HT, Anand A: Primary renal angiosarcoma: a case report with immunohistochemical, ultrastructural, and cytogenetic features and review of the literature. *Archives of pathology & laboratory medicine* 1998, 122(10):929-935
- [54] Aksoy Y, Gursan N, Ozbey I, Bicgi O, Keles M: Spontaneous rupture of a renal angiosarcoma. *Urologia internationalis* 2002, 68(1):60-62
- [55] Aydogdu I, Turhan O, Sari R, Ates M, Turk M: Coincidental acute myeloblastic leukemia in a patient with renal angiosarcoma. *Haematologia* 1999, 29(4):313-317
- [56] Lee TY, Lawen J, Gupta R: Renal angiosarcoma: a case report and literature review. *The Canadian journal of urology* 2007, 14(1):3471-3476
- [57] Berretta M, Rupolo M, Buonadonna A, Canzonieri V, Brollo A, Morra A, Berretta S, Bearz A, Tirelli U, Frustaci S: Metastatic angiosarcoma of the kidney: a case report with treatment approach and review of the literature. *Journal of chemotherapy (Florence, Italy)* 2006, 18(2):221-224
- [58] Souza OE, Etchebehere RM, Lima MA, Monti PR: Primary renal angiosarcoma. *International braz j urol : official journal of the Brazilian Society of Urology* 2006, 32(4):448-450
- [59] Costero-Barrios CB, Oros-Ovalle C: [Primary renal angiosarcoma]. *Gaceta medica de Mexico* 2004, 140(4):463-466
- [60] Grapsa D, Sakellariou S, Politi E: Fine-needle aspiration cytology of primary renal angiosarcoma with histopathologic and immunocytochemical correlation: a case report. *Diagnostic cytopathology* 2014, 42(10):872-876
- [61] Sesar P UM, Šoša S et al.: Primary renal angiosarcoma. *Acta clinica Croatica* 2012, 51(182)
- [62] Yoshida K, Ito F, Nakazawa H, Maeda Y, Tomoe H, Aiba M: A case of primary renal angiosarcoma. *Rare tumors* 2009, 1(2):e28
- [63] Juan CJ YC, Hsu HH, et al. : Visceral and non-visceral angiosarcoma: Imaging features and clinical correlation. *Chin J Radiol* 2000, 25:183-189
- [64] Y.Xuan: Primary renal angiosarcoma: one case report and literatures review. . *Chin J Clin Oncol* 2008, 5::229-300
- [65] Yau T, Leong CH, Chan WK, Chan JK, Liang RH, Epstein RJ: A case of mixed adult Wilms' tumour and angiosarcoma responsive to carboplatin, etoposide and vincristine (CEO). *Cancer chemotherapy and pharmacology* 2008, 61(4):717-720
- [66] Garmendia JC, Lopez Garcia JA, Acinas Garcia O, Garrido Rivas C, Sanroma Ortueta C, Arocena Lanz F: [Angiosarcoma of the kidney]. *Actas urologicas espanolas* 1989, 13(3):223-224
- [67] Nguyen T, Auquier MA, Renard C, Cordonnier C, Saint F, Remond A: [Hemoptysis and spontaneous rupture of a primary renal angiosarcoma: a case report]. *Journal de radiologie* 2010, 91(12 Pt 1):1313-1317
- [68] Limmer S, Wagner T, Leipprand E, Arnholdt H: [Primary renal hemangiosarcoma. Case report and review of the literature]. *Der Pathologe* 2001, 22(5):343-348
- [69] Matter LE, Flury R, Hailemariam S, Hauri D, Sulser T: [Angiosarcoma of the kidney. Case report and review of the literature]. *Der Urologe Ausg A* 1999, 38(1):65-68
- [70] Sanyal B, Mehrotra ML, Gupta S, Pant GC: Radiotherapy in renal angiosarcoma. *Journal of the Indian Medical Association* 1979, 72(4):85-86
- [71] Testa G TG, Tufano A, et al. : Primary renal angiosarcoma: a case report. . *Acta Urologica Italica* 1998, 12:225-227
- [72] Yamamoto Y, Izaki H, Harada A, Taue R, Kishimoto T, Tanimoto S, Fukumori T, Takahashi M, Nishitani MA, Kanayama HO et al : [A case of renal capsular hemangiosarcoma]. *Hinyokika kyo Acta urologica Japonica* 2006, 52(3):215-217
- [73] Rub J, Bauer S, Pastor J, Noldus J, Palisaar RJ: [Primary renal angiosarcoma. Uncommon manifestation of a rare malignancy]. *Der Urologe Ausg A* 2015, 54(6):849-853
- [74] Celebi F, Pilanci KN, Saglam S, Balci NC: Primary renal angiosarcoma with progressive clinical course despite surgical and adjuvant treatment: A case report. *Oncology letters* 2015, 9(4):1937-1939
- [75] Li N, Li W, Li Z: [Primary renal epithelioid angiosarcoma with transitional cell carcinoma in renal pelvis]. *Zhonghua wai ke za zhi [Chinese journal of surgery]* 1997, 35(5):294-295
- [76] Witczak W, Szubstarski F, Szymanski C, Rajca Z, Staszczuk S: [Renal hemangiosarcoma]. *Polski tygodnik lekarski (Warsaw, Poland : 1960)* 1993, 48(20-22):483-484
- [77] Cuadra-Urteaga JL, Font A, Tapia G, Areal J, Taron M: Carcinosarcoma of the upper urinary tract with an aggressive angiosarcoma component. *Cancer biology & therapy* 2016, 17(3):233-236
- [78] Su YC: Angiosarcoma of kidney with calcification: A rare case report. *The Kaohsiung journal of medical sciences* 2017, 33(7):367-368